




Neurologic Manifestations of Rheumatoid Arthritis: A Case of Cerebral Vasculitis Treated With Rituximab

Mohamad Ali RIDA , Maysam El NAJJAR , Mira MERASHLI 

Department of Rheumatology, American University of Beirut Medical Center, Beirut, Lebanon

Autoimmunity and the overall state of chronic inflammation are associated with many extra-articular manifestations.¹ Rheumatoid vasculitis is probably the rarest yet the most severe extraarticular manifestation and is usually observed in patients with long-standing, uncontrolled seropositive disease.² In this article, we describe the case of a 61-year-old female patient diagnosed with seropositive long-standing rheumatoid arthritis presented to our hospital recently and episodic fluctuations of altered level of consciousness of one week duration, initially

diagnosed to have bacterial meningitis based on cerebrospinal fluid analysis with superimposed pneumonia and started on antibiotics with no improvement. Patient is known to have multiple rheumatoid nodules in her chest, followed-up by serial computed tomography scans. Magnetic resonance imaging (MRI) of the brain upon admission showed multiple confluent high fluid-attenuated inversion recovery (FLAIR) signals in the periventricular white matter, hippocampal gyrus and peritrigonal regions of both cerebral hemispheres (Figure 1). In light of the patient's

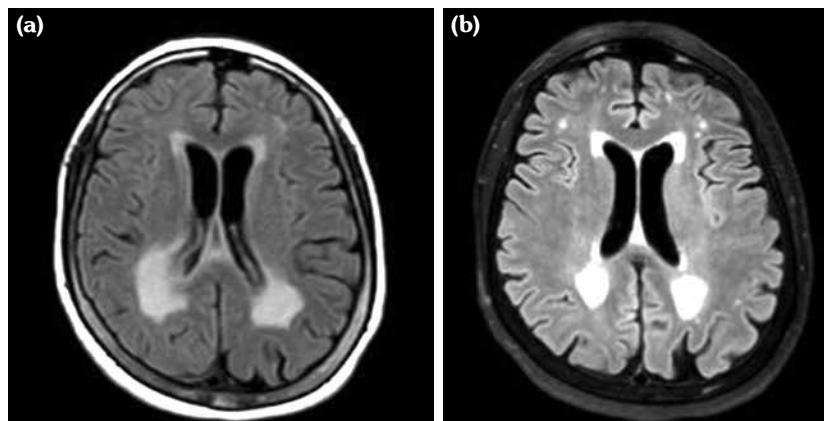


Figure 1. Brain magnetic resonance imaging, (a) before and (b) after treatment with intravenous steroids and rituximab. Further decrease in the FLAIR signal surrounding the lateral ventricles and in the areas of enhancement.

Received: March 15, 2018 **Accepted:** March 26, 2018 **Published online:** May 07, 2018

Correspondence: Mira Merashli, MD. Department of Rheumatology, American University of Beirut Medical Center, 11-0236 Beirut, Lebanon.
Tel: 009613439033 e-mail: mm116@aub.edu.lb

Citation:

Rida MA, Najjar ME, Merashli M. Neurologic manifestations of rheumatoid arthritis: a case of cerebral vasculitis treated with rituximab. Arch Rheumatol 2019;34(2):238-240.

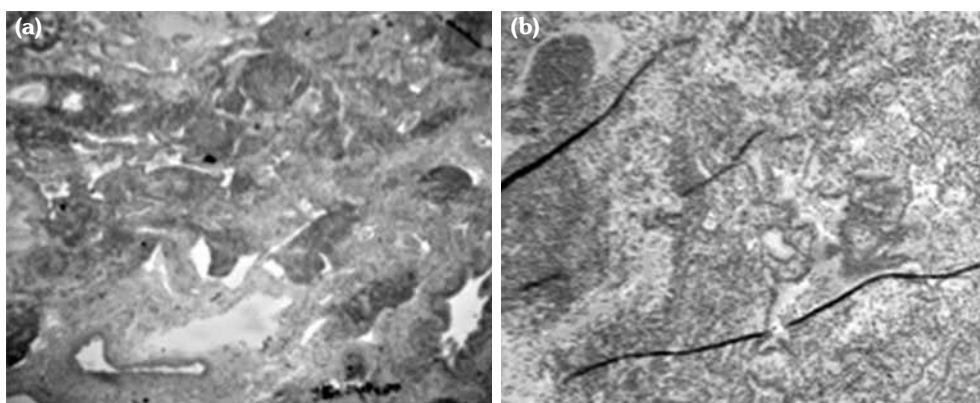


Figure 2. Lung biopsy. Formalin. **(a)** Areas of interstitial inflammation alternating with areas of normal lung. **(b)** Prominent lympho-plasmacytic infiltrates (H-E×100).

known diagnosis of rheumatoid arthritis, these findings were compatible with an inflammatory process consistent with rheumatoid vasculitis. Repeated cerebrospinal fluid analysis after antibiotics treatment indicated increased number of inflammatory cells, mainly lymphocytes and monocytes. Open lung biopsy revealed active chronic interstitial pneumonitis (Figure 2). It was then decided to start our patient on steroids: intravenous methylprednisolone 40 mg push twice daily and antibiotics were discontinued with the diagnosis of rheumatoid cerebral vasculitis. She was then discharged on prednisone 40 mg orally once daily.

Repeated MRI of the brain one month later displayed significant decrease in the high FLAIR signals. Repeated lumbar puncture and cerebrospinal fluid analysis three months later demonstrated mature lymphocytes and occasional monocytes. Decision was to proceed with rituximab infusions as a steroid-sparing agent. Repeated MRI and cerebrospinal fluid studies three months after first cycle of rituximab showed significant improvement. Cerebral vasculitis is a rare complication of rheumatoid arthritis with frequency ranging between 1% and 8%.³ The damage in the endothelium may trigger thrombus formation which might result in ischemia or hemorrhage in the area served by the vessel that can be seen on the macroscopic level.⁴ Rheumatoid vasculitis is most commonly seen in seropositive females with destructive and erosive rheumatoid arthritis associated with subcutaneous nodules and other extraarticular manifestation.⁴

A biopsy is required for a definitive diagnosis of cerebral vasculitis. However, it is not always feasible and mostly based on cerebrospinal fluid and cerebral imaging studies. Cerebrospinal fluid would demonstrate lymphocytosis and protein elevation which implies an underlying inflammation. There are no clear guidelines when it comes to treatment of cerebral vasculitis in rheumatoid arthritis. However, glucocorticoids have been commonly used such as pulse methylprednisolone.⁵ In a study carried out by Puéchal et al.,⁶ complete remission of cerebral rheumatoid vasculitis was observed in 12 out of 17 patients receiving rituximab. Our patient had significant response on intravenous methylprednisolone and rituximab that was shown by repeated MRI of the brain.

Declaration of conflicting interests

The authors declared no conflicts of interest with respect to the authorship and/or publication of this article.

Funding

The authors received no financial support for the research and/or authorship of this article.

REFERENCES

1. Turesson C. Extra-articular rheumatoid arthritis. *Curr Opin Rheumatol* 2013;25:360-6.
2. Ntatsaki E, Mooney J, Scott DG, Watts RA. Systemic rheumatoid vasculitis in the era of modern immunosuppressive therapy. *Rheumatology (Oxford)* 2014;53:145-52.

3. Watts RA, Mooney J, Lane SE, Scott DG. Rheumatoid vasculitis: becoming extinct? *Rheumatology (Oxford)* 2004;43:920-3.
4. Guadalupe Loya-de la Cerda D, Avilés-Solís JC, Delgado-Montemayor MJ, Camara-Lemarroy CR, Galarza-Delgado DÁ. Isolated rheumatoid arthritis-associated cerebral vasculitis: a diagnostic challenge. *Joint Bone Spine* 2013;80:88-90.
5. Ozkul A, Yilmaz A, Akyol A, Kiylioglu N. Cerebral vasculitis as a major manifestation of rheumatoid arthritis. *Acta Clin Belg* 2015;70:359-63.
6. Puéchal X, Gottenberg JE, Berthelot JM, Gossec L, Meyer O, Morel J, et al. Rituximab therapy for systemic vasculitis associated with rheumatoid arthritis: Results from the AutoImmunity and Rituximab Registry. *Arthritis Care Res (Hoboken)* 2012;64:331-9.