

## Pauci-immune Crescentic Glomerulonephritis in a Patient With Immunoglobulin A Nephropathy and Serum Antineutrophil Cytoplasmic Autoantibody Positivity

Keren COHEN-HAGAI,<sup>1</sup> Sydney BENCHETRIT,<sup>1</sup> Osnat KLEIN,<sup>1</sup> Yona KITAY-COHEN,<sup>2</sup> Ze'ev KORZETS<sup>1</sup>

<sup>1</sup>Department of Nephrology, Meir Medical Center, Kfar Saba, Israel

<sup>2</sup>Department of Internal Medicine C, Meir Medical Center, Kfar Saba, Israel

Immunoglobulin A nephropathy (IgAN) is the most prevalent form of primary glomerulopathy worldwide.<sup>1</sup> Antineutrophil cytoplasmic autoantibodies (ANCA) are commonly associated with vasculitis [ANCA associated vasculitis (AAV)] and a pauci-immune crescentic glomerulonephritis. The co-existence of IgAN and AAV is rare. In this report, we describe the clinical course and treatment of a patient with such an association.

A 65-year-old male patient was referred for evaluation of a serum creatinine of 1.32 mg/dL. Antinuclear antibodies were positive in a low titer (1:40) and perinuclear ANCA tested positive on indirect immunofluorescence at a titer of 1:160. Anti-myeloperoxidase antibodies measured 108 units (normal range 0-20) by enzyme-linked immunosorbent assay. Urinalysis showed hematuria and proteinuria (652 mg/24-hour). Renal biopsy showed mild focal glomerular mesangial expansion. There were no crescents or evidence of vasculitis. On immunofluorescence, there was moderately intense staining for IgA in the mesangium (Figure 1a). These findings were consistent with the diagnosis of IgAN. The patient was administered a six-month course of steroids. This, however, resulted in no improvement in his proteinuria or glomerular filtration rate.

Over the following four years, a progressive increase in serum creatinine was noted, initially at a slow rate (1.32 mg/dL to 1.63 mg/dL) over two years and then at an accelerated pace (1.82 mg/dL to a peak 6.5 mg/dL) over six months. Proteinuria at this stage was 6897 mg/24-hour. A repeat renal biopsy was performed. This time, there were 14 glomeruli of which 10 (71.4%) had a cellular crescent (Figure 1b). Immunofluorescence for IgG, IgM, IgA, and complement components 3 and 4 were negative.

With the diagnosis of a perinuclear ANCA associated pauci-immune crescentic glomerulonephritis, the patient was administered steroids and intravenous cyclophosphamide. On this treatment, serum creatinine declined to his current 3.05 mg/dL. In parallel, perinuclear ANCA at this stage was found to be negative.

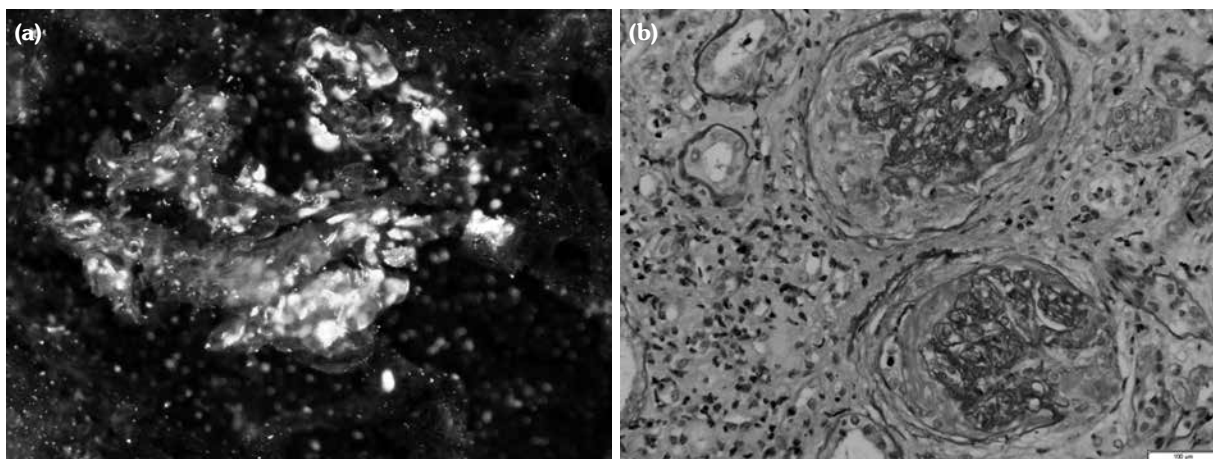
Despite the common prevalence of both IgAN and AAV as separate entities, their co-existence is rare. In fact, to our knowledge, no more than 50 cases of co-existing IgAN and ANCA serum positivity have been described thus far. These consist mainly of case reports and three case series.<sup>2-4</sup> Haas et al.<sup>2</sup> reported six patients with more than 50% crescents of glomeruli. The histological features and clinical response to aggressive immunosuppressive treatment

**Received:** May 07, 2017 **Accepted:** May 09, 2017 **Published online:** September 13, 2017

**Correspondence:** Ze'ev Korzets, MD. Department of Internal Medicine C, Meir Medical Center, 44281 Kfar Saba, Israel.

Tel: 97297472517 e-mail: korzets.zeev@gmail.com

©2018 Turkish League Against Rheumatism. All rights reserved.



**Figure 1.** (a) Immunofluorescence of kidney biopsy demonstrating a moderately intense staining for immunoglobulin A in mesangium. (b) Periodic acid-Schiff staining demonstrating cellular crescents in two glomeruli and inflammatory infiltrate in surrounding interstitium.

resembled AAV. In a retrospective study of 393 patients with biopsy proven IgAN, Bantis et al.<sup>3</sup> found eight with ANCA positivity (five anti-myeloperoxidase and three anti-proteinase 3). They were compared to 26 IgAN patients with negative ANCA and >10% crescentic glomeruli. Similar to Haas et al.'s series,<sup>2</sup> those with ANCA positivity were characterized by a more severe clinical course and histological lesions but a better response to therapy. Similar conclusions were also reached by Yang et al.,<sup>4</sup> who compared 20 ANCA positive IgAN patients to 40 ANCA negative IgAN patients and 40 AAV patients.

Whether the association of IgAN with ANCA positivity is coincidental or representative of a novel entity remains an open question. Elevated levels of serum tumor necrosis factor, soluble forms of intercellular adhesion molecule 1 and urinary interleukin-8 have been documented in the deteriorating phase of IgAN. Potentially, these could lead to activation of polyclonal B cells and the formation of ANCA.<sup>5</sup> Interestingly, the pauci-immune glomerulonephritis demonstrated in our patient's second biopsy was devoid of IgA deposits. IgAN is usually typified by lifelong persistence of IgA deposits. Regression of these deposits has, however, been reported in IgAN presenting with a nephrotic syndrome after steroid induced remission.<sup>6</sup> One possible explanation for the disappearance of the IgA deposits is their degradation by enzymes provoked by the

immune response to ANCA.<sup>4</sup> In conclusion, the coexistence of IgAN and AAV is rare and should be treated as AAV.

#### Declaration of conflicting interests

The authors declared no conflicts of interest with respect to the authorship and/or publication of this article.

#### Funding

The authors received no financial support for the research and/or authorship of this article.

## REFERENCES

1. Tumlin JA, Madaio MP, Hennigar R. Idiopathic IgA nephropathy: pathogenesis, histopathology, and therapeutic options. *Clin J Am Soc Nephrol* 2007;2:1054-61.
2. Haas M, Jafri J, Bartosh SM, Karp SL, Adler SG, Meehan SM. ANCA-associated crescentic glomerulonephritis with mesangial IgA deposits. *Am J Kidney Dis* 2000;36:709-18.
3. Bantis C, Stangou M, Schlaugat C, Alexopoulos E, Pantzaki A, Memmos D, et al. Is presence of ANCA in crescentic IgA nephropathy a coincidence or novel clinical entity? A case series. *Am J Kidney Dis* 2010;55:259-68.
4. Yang YZ, Shi SF, Chen YQ, Chen M, Yang YH, Xie XF, et al. Clinical features of IgA nephropathy with serum ANCA positivity: a retrospective case-control study. *Clin Kidney J* 2015;8:482-8.
5. Shimizu M, Wada T, Sakai N, Izumiya Y, Furuichi K, Misaki T, et al. Clinicopathological features of

antineutrophil cytoplasmic antibodies associated vasculitis in Japanese patients with IgA nephropathy. *Clin Exp Nephrol* 2000;4:251-6.

6. Cheng IK, Chan KW, Chan MK. Mesangial IgA

nephropathy with steroid-responsive nephrotic syndrome: disappearance of mesangial IgA deposits following steroid-induced remission. *Am J Kidney Dis* 1989;14:361-4.