

## Case Report

## A Pre- and Postoperative Evaluation of Multiple Joint Involvement as the Initial Finding of Cervical Syringomyelia and Neuropathic Arthropathy

### Servikal Siringomiyelin ve Nöropatik Artropatinin İlk Bulgusu Olarak Ortaya Çıkan Çoklu Eklem Tutulumunun Ameliyat Öncesi ve Sonrası Değerlendirilmesi

Ayşin KISABAY,<sup>1</sup> Sinem ZEYBEK,<sup>1</sup> Serpil SARI,<sup>1</sup> Aliye TANYELİ,<sup>2</sup> Deniz SELÇUKİ<sup>1</sup>

<sup>1</sup>Department of Neurology, Medical Faculty of Celal Bayar University, Manisa, Turkey

<sup>2</sup>Department of Physical Medicine and Rehabilitation, Medical Faculty of Celal Bayar University, Manisa, Turkey

Syringomyelia is a progressive, degenerative disorder, in which a longitudinal cyst forms within the spinal cord. Neuropathic arthropathy can be seen in the late phases of the disease, with the most frequent involvement being in the shoulder. Herein, we present a 42-year-old female case who was diagnosed with syringomyelia as well as Arnold-Chiari Syndrome and neuropathic arthropathy. Her initial complaints were painless edema in the right shoulder and elbow, wounds on the tips of her fingers and amputations. She was evaluated both pre- and postoperative periods. It should be kept in mind that neuropathic arthropathy may develop as the initial symptom in spinal cord lesions which progress slowly.

Key words: Arnold-Chiari Syndrome; neuropathic arthropathy; syringomyelia.

Charcot arthropathy (also known as neuropathic osteoarthropathy or neuropathic arthropathy) is a progressive, degenerative arthritis associated with an underlying central or associated neurological disease that affects the peripheral or spinal joints.<sup>[1]</sup> It was first reported in 1868 by Charcot in a case<sup>[1]</sup> that involved tabes dorsalis and is especially characterized by progressive osteoclasts, bone resorption, and deformity. In addition, it causes pain and loss of feeling in the affected region. Charcot arthropathy is also a degenerative chronic disease, and many reports

Syringomiyeli spinal kordun içerisinde longitudinal kistin oluştuğu, progresif dejeneratif bir hastalıktır. En sık omuz eklem tutulumu görülen bu hastalığın ilerleyen dönemlerinde nöropatik artropati gelişimi söz konusudur. Bu yazıda, siringomiyeli, Arnold-Chiari Sendromu ve nöropatik artropati tanısı konulan 42 yaşında kadın bir olgu sunuldu. Hastanın ilk yakınmaları olarak sağ omuzda ve dirsekte ağrısız ödem, parmak uçlarında yara ve amputasyonlar vardı. Hasta siringomiyeli ameliyatı öncesi ve sonrası değerlendirildi. Yavaş ilerleyen spinal kord lezyonlarında ilk bulgu olarak nöropatik artropatinin çıkabileceği göz önünde bulundurulmalıdır.

Anahtar sözcükler: Arnold-Chiari Sendromu; nöropatik artropati; siringomiyeli.

exist which describe the various disorders that are associated with this type of arthritis.<sup>[1,2]</sup>

Syringomyelia is a progressive, slow-advancing disease which most frequently affects the shoulder joint but not the central nerve system but also the central nerve system. It may also cause multiple joint exposures in the elbows and hands.<sup>[3-5]</sup> In tabes dorsalis, diabetes mellitus (DM), alcoholic neuropathy, leprosy, syphilis, myelomeningocele, syringomyelia, and intra-articular steroid injections are the other causes of Charcot arthropathy.<sup>[1,2,6,7]</sup>

**Received:** September 12, 2012 **Accepted:** December 04, 2012

**Correspondence:** Serpil Sari, M.D. Celal Bayar Üniversitesi Tıp Fakültesi Nöroloji Anabilim Dalı, 45030 Manisa, Turkey.

Tel: +90 505 - 519 80 37 e-mail: dr.serpilsari@hotmail.com

©2013 Turkish League Against Rheumatism. All rights reserved.

Our case is interesting because of the symptoms which occurred in the later period of the disease, the comorbidity of acral mutilations, the existence of Charcot arthropathy in the shoulder and elbow, and the association with sensory motor polyneuropathy. In addition, our patient was operated on as a result of the syringomyelia, and the pre- and postoperative neurological examinations and findings were evaluated. However, there still is a need for long-term follow-up after the surgery.

### CASE REPORT

A 42-year-old female patient was admitted to our clinic with numbness in her arms, redness on her right shoulder, and swelling and limited mobility in her right shoulder and elbow as well as non-healing wounds on her fingers. She had been suffering from the non-healing wounds and ruptures without pain for five years, and these had progressively spread to both of her hands and become more prominent on the right hand and fingertips. Furthermore, the patient had spontaneously burned her hands while cooking because of the lack of less feeling. The complaints of progressively increasing numbness, weakness, rubor, erythema, and swelling on the right shoulder and arm that started 10-15 days before admission to our hospital were in addition to the numbness and insensitivity to heat in both hands beginning from the elbows. The patient was hospitalized in the neurology department.

In the patient's history, she had fractured her forearm three years earlier, but this healed over time without applying a cast. Furthermore, a physical examination revealed swelling, increased heat, erythema, and crepitation in the right shoulder as well as pain and swelling in the right elbow joint. The patient also underwent a neurological examination which showed she was conscious, cooperative, and oriented. An inspection of her cranial nerve yielded normal results except that she tested positive for horizontal nystagmus when looking to the left and to the right. Due to the swelling and pain in the right shoulder, her shoulder abduction was limited (4/5) according to manual muscle testing, but she tested within normal limits in her other muscles. Additionally, a glove- or stocking-like sensory defect was detected in her hands and feet, and a cloak-like cold-hot sensory disorder was identified in the shoulder region. Her deep tendon reflexes were also increased in the upper extremities but decreased in the lower extremities. Furthermore, the patient's extensor

plantar skin response was bilateral, and there was pes cavus deformity in her right foot. Finally, acral mutilations were apparent on both hands, but they were more noticeable on her right hand (Figure 1).

An examination of the locomotor system disclosed that the patient's joint range of motion in the lower extremities was open in all directions, and she experienced no pain. However, in the upper extremities, there was swelling in the right shoulder along with an increase in heat, and the joint movement was painful and limited in every direction. Her active right shoulder flexion measured 10 degrees while the abduction and extension measured only 5 degrees. Passively, the right shoulder flexion measured 40 degrees but only 30 degrees at abduction. In addition, the interior and exterior rotation measured 20 degrees. Other joint movements in the upper extremity were found to be open and painless. However, there was crepitation in the shoulder when it was moved in all directions.

The patient's laboratory examination revealed the following: white blood cell (WBC): 15,400, hemoglobin: 9.8 g/dl (range 11-18 g/dl), hematocrit: 27.5% (range 35-57%), mean corpuscular volume (MCV): 70.3 fL (range 80-99 fL), erythrocyte sedimentation rate (ESR): 43 mm/hour, iron: 21 ug/dl (range 50-170 ug/dl), antistreptolysin O (ASO): 357 IU/ml (range 0-200 IU/ml), and C-reactive protein (CRP): 24.4 mg/l (range 0-5). In addition, the results were within normal limits for the liver, kidney, and thyroid function tests, and the cardiac enzyme, B12, and folic acid levels were also normal. A complete urinalysis also showed no abnormalities. Furthermore, the hepatitis and vasculitis indicators were negative as were the tests for Brucella, Salmonella, and syphilis. Moreover, the immunofluorescence and protein electrophoreses were also within normal

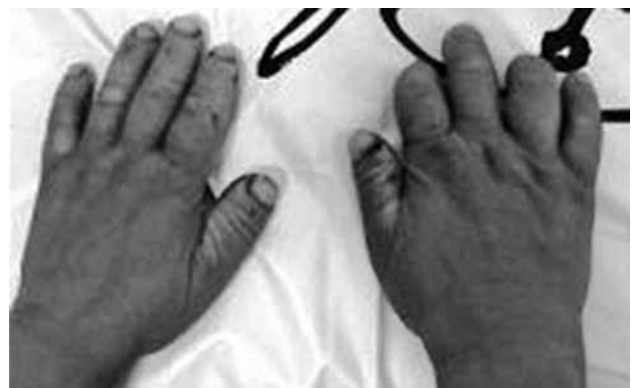
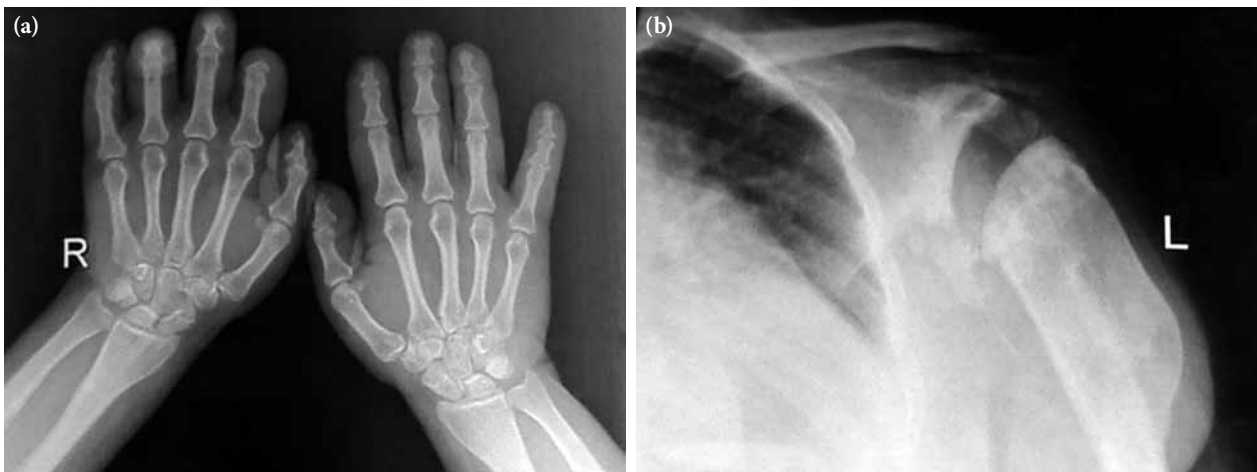
Figure 1. Changes and acral mutilations in the patient's hands.



**Figure 2.** X-rays showing the destructive changes in (a) the hands and (b) the shoulder joint.

limits, and, the cerebrospinal fluid (CSF) results after lumbar puncture were also normal.

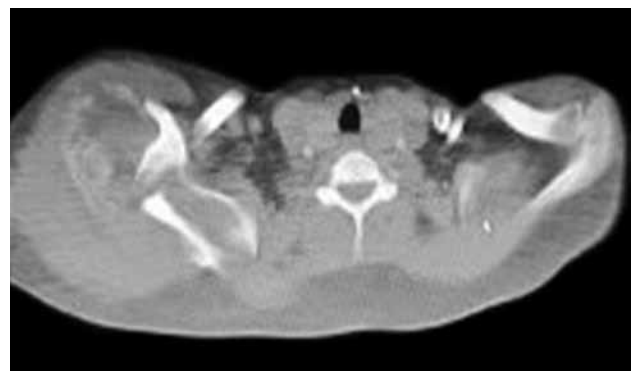
An electrophysical examination showed bilateral moderate slowing in the macular fibers during a visual evoked potential (VEP) test and a total conduction block in the fasciculus gracilis on the somatosensory evoked potential (SEP) test. In addition, there were also some SEPS findings related to sensory motor polyneuropathy accompanied by axonal degeneration. While sympathetic skin responses were recorded from the upper extremities, the opposite was the case for the lower extremities. Furthermore, the patient had no history of hereditary polyneuropathy. Moreover, an examination to determine the etiology of the sensory motor polyneuropathy revealed no significant pathology.

Radiological examinations showed destruction in the joints and bone structure of the affected right shoulder, elbow, and wrist as well as soft tissue calcification (Figure 2). Upper extremity computed tomography (CT) also indicated that the bilateral glenohumeral joint relations were disturbed. The joint on the right was dislocated, and both humeral heads were destructed and fragmented, with the damage more visible on the right side. Furthermore, extensive soft tissue calcification was noted in the neighborhood of the joints together with destructive changes in the glenoid fossa and proximal humeral metaphysis. Additionally, the lesions that showed bilaterally similar but moderately asymmetric involvement were evaluated with regard to neuropathic arthropathy (Figure 3).

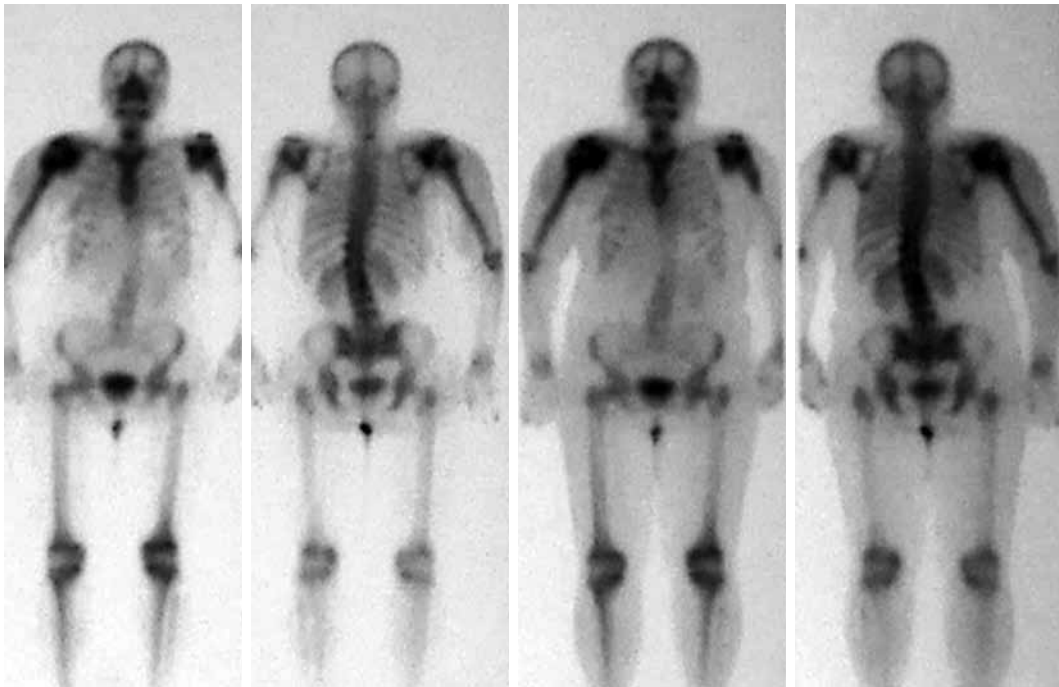
In the scintigraphic examination, we found increased activity involvement in both shoulders,

especially in the right shoulder as well as on the right humeral head and in the distal phalanx of the finger. Both the scintigraphic and the radiological findings were compatible with secondary degenerative changes, especially in the benign bone pathologies (Figure 4). Furthermore, craniocervical magnetic resonance imaging (MRI) (especially FLAIR sequence) found cerebellar tonsillar herniation compatible with the Chiari type I malformation in the accompanying syrinx cavity in the cervical spinal cord (Figure 5). In addition, the arterial/venous Doppler ultrasonography (USG) results for both the lower and upper extremities were normal.

In light of the patient's history and laboratory findings, she was diagnosed with Arnold-Chiari type I syringomyelia and Charcot arthropathy. The patient was evaluated by neurosurgery consultants, and surgery was recommended. However, since the patient did not accept this option, she was started on medical treatment and subsequently followed



**Figure 3.** Computed tomography showing the changes in the glenohumeral joints in the right shoulder.



**Figure 4.** Complete body scintigraphy showing the increased activity retention in the joints.

up. Anti-inflammatory treatment was given for the pain and limited joint mobility, and this provided some relief. Unfortunately, one month after being discharged from our clinic, the patient had to undergo a foramen magnum decompression procedure performed via a suboccipital craniectomy along with a cerebellar tonsillectomy and duraplasty in the neurosurgical clinic due to the persistence of her symptoms.

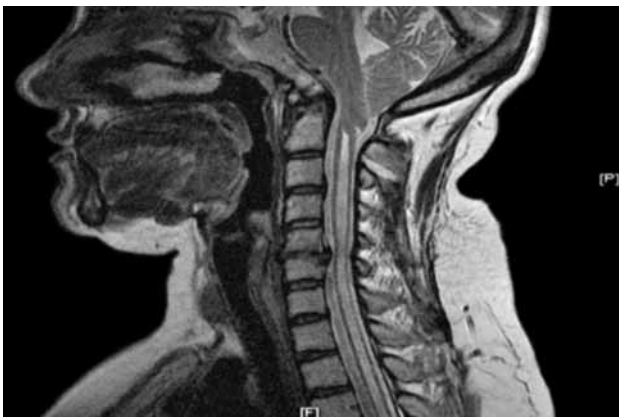The pain in her shoulder and arm decreased after the operation, and she was able to move better. Although she still suffered from limited shoulder

mobility, there was slight improvement when she fed herself with a spoon compared with her preoperational state. No significant changes were seen in her neurological examination after the surgery, but her locomotor system examination revealed no swelling, and an increased sense of heat in her right shoulder was also observed. Her active joint range of motion was measured again, with the abduction calculated as 90 degrees, the flexion as 100 degrees, and the extension as 30 degrees without pain. Furthermore, there was no limitation in her passive joint motion range, but crepitation was present when she moved her shoulder in all directions. However, the cracking sounds were less than they had been in the pre-operational state due to a reduction in the synovial fluid. The swelling around the right shoulder and the sensation of heat were still present.

## DISCUSSION

Syringomyelia is a chronic, progressive spinal cord disease characterized by longitudinal cavitations. It especially affects the cervical regions and is seen in conjunction with Chiari type I malformation in 75-85% of patients.

Neurological symptoms develop according to the location and length of the syrinx. At first, sensory impairment occurs followed by numbness, burning,



**Figure 5.** Craniocervical magnetic resonance imaging (FLAIR sequence) showing the syringomyelia.

arthrophy, and neuropathic pain in the later periods of the disease. In the spinal cord, a sensation of heat and pain pass through the middle of the medulla spinalis. Since the center of the structure is affected in the syrinx, pain and heat impairment then develop.<sup>[1,2,4]</sup>

Syringomyelia affects the shoulder joints, and in 3-8% of cases, it may also affect the elbows and its joints. Additionally, involvement of the wrist and hand joints as well as isolated ulnar neuropathies have been reported in some cases in the literature.<sup>[3,8-10]</sup>

Upper and lower motor neuron lesions associated with syringomyelia may lead to arthropathy, which frequently involves the weight-bearing joints of the body. Central sensorial lesions can be caused by multiple sclerosis (MS), syringomyelia, tabes dorsalis, leprosy, congenital lack of response to the pain, cerebral palsy, or a spinal cord injury, whereas peripheral sensorial lesions are caused by DM, alcoholism, infections, poliomyelitis, pernicious anemia, or amyloidosis. Moreover, the arthropathy frequently affects the weight-bearing joints of the body.<sup>[1,2,6,10,11]</sup>

The pathogenesis of Charcot arthropathy has not been clearly definitely as of yet. Its most apparent characteristic is that there is no sensation of pain, but swelling and deformations have also been noted. There are two accepted principal theories regarding this topic. One is the widely accepted neurotrauma theory in which progressive destruction, hemarthrosis, synovial thickening, and secondary ligament laxity develop after recurrent traumas in the joints where normal pain perception and proprioception are impaired. Secondary bacterial infections may also develop in the same areas, which can cause pathologies such as cellulitis, abscesses, and osteomyelitis.<sup>[1,2,6,11,12]</sup>

The neurovascular theory is another theory, but it is not as popular. It states that sympathetic system regulation in the blood flow of the foot bones is impaired in connection with autonomic neuropathy. The blood flow in the foot bones is increased as sympathetic vasoconstriction disappears. Both bone destruction (osteoclastic activity) and bone construction (osteoblastic activity) occur, but destruction is more prevalent. As a result, weakness in bone tissue and hyperemic demineralization take place, and the continual weakness in the bone tissue creates a predisposition toward injuries and fractures.<sup>[1,2,6,11,12]</sup>

Microtraumas that recur as a result of the loss of peripheral sensation can lead to inflammatory resorption and weakened bones. Furthermore, the lack of fine motor control and abnormal overloads can cause damage in the joints. As a result of the uncontrolled peripheral autonomic nerve system, the vessel cannot regulate its diameter, resulting in increased blood flow to the joint. Bone resorption increases with the hyperemia, which is caused most frequently by DM. Hence, an MRI of the affected part of the body along with a complete body scintigraphy are vital for diagnosing Charcot arthropathy.<sup>[13]</sup>

In the radiological examination, destruction, dislocation, sclerosis, and organizational dysfunction in the joint are often observed, especially in the later phases of the arthropathy. According to Jones et al.,<sup>[14]</sup> hypertrophy associated with Charcot arthropathy consists of six D's: distended joints, density increase, dislocation, debris formation, disorganization of the joint structure, and destruction. The existence of atrophy and hypertrophy in the joints indicates that there are two abnormalities linked to this disorder<sup>[1,14]</sup> Based on the aforementioned criteria, our case was considered to be related to phase 3-4 and the atrophy.

Radiological findings with Charcot arthropathy can be either hypertrophic (productive) or atrophic (destructive). Hypertrophic changes occur together with trauma and spinal cord lesions such as tumors or congenital malformations; however, atrophic changes are seen with alcoholism, DM, and trauma.<sup>[1,14]</sup>

Destruction in the affected joints and bones along with the soft tissue involvement may be observed via direct X-rays. Charcot arthropathy has been divided into three phases by Eichenholtz.<sup>[15]</sup> Phase 1 is a hypervascular phase that occurs at the beginning of the disease. In this phase, only joint laxity is generally observed, with osteochondral fragmentation and debris formation being seen in rare cases. In phase 2, recurrent microtraumas are preponderant. Debris absorption, fusion of large bone fragments, sclerosis, and avascular necrosis in the subcondral bones as well as increased bone density indicating new bone formation are the principal radiological findings in this phase. Phase 2 is also known as the fusion phase. In phase 3, reconstruction and restructuring take place. Our case was in phase 2 after the examinations,<sup>[2,12,13]</sup> and after repeated traumas, acral mutilation developed.

It is very important to be able to observe the effusion and cartilage fragmentation that forms in the

joints in the early periods of Charcot arthropathy. As the disease progresses, bone collapse becomes more apparent, and sclerosis and intrajoint bone fragments, massive soft tissue edema, and microfractures in the neighboring bones are observed. In our patient, who was in a later phase of this disorder, bone collapse and sclerosis were observed.<sup>[2,12,13]</sup>

In our case, as in others with syringomyelia, the existence of increased heat in the shoulder joint, hyperemia and pain in the elbow joint, crepitation, joint limitation, and destruction were remarkable. In addition, our patient's bone and shoulder scintigraphy results were compatible with other cases in the literature.

Osteoarthritis, neoplasia, osteomyelitis, septic arthritis, hemarthrosis, and gout are considered to be distinguishing characteristics in the diagnosis of Charcot arthropathy. In addition, a patient's history together with the physical examination and radiological tests (MRI, bone scintigraphy) are also crucial. The radiological aspects are similar with Charcot arthropathy and syringomyelia, and the joint pain associated with these diseases does not differ.<sup>[12,13,16]</sup>

Syringomyelia, which was accompanied by Chiari type I malformation and Charcot arthropathy in our patient, is an insidious disease that progresses very slowly, but it is generally painless. It was identified in our patient incidentally, but by the time it was diagnosed, the disease was already in the later phase.

The treatment is conservative in most syringomyelia cases, but physical therapy and surgical interventions are also recommended for some patients. The important thing is to treat the underlying disease and stop the progression of joint degeneration and deformity, and non-steroid anti-inflammatory drugs (NSAIDs) usually achieve these two goals. In our patient, a partial decrease in the swelling and reddening in the shoulder and elbow joints was observed after the use of anti-inflammatory drugs.

In the examination after the surgical intervention, the crepitation had decreased in the shoulder joint, and we identified the cause of the neuropathic arthropathy as being the syringomyelia. This disease is primarily treated surgically. After originally declining this option, our patient underwent surgery one month later due to the continuation of

her symptoms, and she was reevaluated after the operation. However, no significant differences were found in the neurological evaluations carried out at the time of the operation and two months later, but long-term follow-up is recommended.<sup>[2]</sup>

Kwon and Morrey<sup>[17]</sup> stated that surgery for Charcot arthropathy might be useful for some patients but added that it is not the first option and that functional devices and physical therapy must be tried first.

### Conclusion

We believe that our case was unique due to the appearance of the symptoms in the late phase of the syringomyelia, the comorbidity of acral mutilations, the existence of Charcot arthropathy in the shoulder and the elbow, and the association with sensory motor polyneuropathy. Charcot arthropathy must be considered in patients with syringomyelia, especially in cases with destructive arthropathy without noticeable complaints of pain as well as craniocervical junction anomalies and neurological diseases such as underlying Arnold-Chiari type I syringomyelia since this may cause symptoms such as were seen in our patient.

### Declaration of conflicting interests

The authors declared no conflicts of interest with respect to the authorship and/or publication of this article.

### Funding

The authors received no financial support for the research and/or authorship of this article.

---

## REFERENCES

1. Nacir B, Arslan Cebeci S, Cetinkaya E, Karagoz A, Erdem HR. Neuropathic arthropathy progressing with multiple joint involvement in the upper extremity due to syringomyelia and type I Arnold-Chiari malformation. *Rheumatol Int* 2010;30:979-83.
2. Grahovac G, Vilendecic M, Srdoc D. Charcot shoulder caused by Chiari type I malformation with syringomyelia with six-year follow-up. *Wien Klin Wochenschr* 2011;123:512-4.
3. Ekim A, Armağan O. Neuropathic arthropathy caused by syringomyelia in different joints and lesion of brachial plexus at right upper extremity: a case report. *Agri* 2007;19:54-8.
4. Butteriss DJ, Birchall D. A case of syringomyelia associated with cervical spondylosis. *Br J Radiol* 2006;79:e123-5.
5. Yağcı İ, Özkök Ö, Üstün I, Ağırman M, Gündüz H, Akyüz G. Siringomyeliye bağlı el-el bileği nöropatik artropatisi. *Turk J Phys Med Rehab* 2009;55:176-8.

6. Yanik B, Tuncer S, Seçkin B. Neuropathic arthropathy caused by Arnold-Chiari malformation with syringomyelia. *Rheumatol Int* 2004;24:238-41.
7. Noain E, Martínez de Morentín J, Artázcoz FJ, Gozzi S, Lasanta P, Sánchez-Villares JJ. Neuropathic arthropathy of the shoulder. *An Sist Sanit Navar* 2007;30:487-90. [Abstract]
8. Dilek A, Aydoğan A, Çetin N, Akman M. N. Servikal siringomyelinin ilk bulgusu olarak ortaya çıkan dirsekte nöropatik artropati: Bir Olgu sunumu. *Turk J Phys Med Rehab* 2007;53:172-4.
9. Scelsa SN. Syringomyelia presenting as ulnar neuropathy at the elbow. *Clin Neurophysiol* 2000;111:1527-30.
10. Clayton M, Taylor BC, Backes J. Diabetic neuroarthropathy of the shoulder. *Orthopedics* 2010;33.
11. Brower AC, Allman RM. Pathogenesis of the neurotrophic joint: neurotraumatic vs. neurovascular. *Radiology* 1981;139:349-54.
12. Sackellares JC, Swift TR. Shoulder enlargement as the presenting sign in syringomyelia. Report of two cases and review of the literature. *JAMA* 1976;236:2878-9.
13. Akgün U, Kocaoğlu B, Erol B, Karahan M, Esemeli T. Diabetes mellitus'lu pediatrik hastada gelişen Charcot Artropatisi: Olgu Sunumu. *Acıbadem Üniversitesi Sağlık Bilimleri Dergisi* 2010;1:38-42.
14. Jones EA, Manaster BJ, May DA, Disler DG. Neuropathic osteoarthropathy: diagnostic dilemmas and differential diagnosis. *Radiographics* 2000;20:S279-93.
15. Eichenholtz SN. Charcot joints. Springfield, IL: CC Thomas; 1966.
16. Barber DB, Janus RB, Wade WH. Neuroarthropathy: an overuse injury of the shoulder in quadriplegia. *J Spinal Cord Med* 1996;19:9-11.
17. Kwon YW, Morrey BF. Neuropathic elbow arthropathy: a review of six cases. *J Shoulder Elbow Surg* 2006;15:378-82.