



Deficiency of interleukin-1 receptor antagonist: A systematic review

Wérgila Ruana Gonçalves Barros¹, Jucier Gonçalves Júnior^{2,3}

¹Department of Internal Medicine, Escola de Saúde Pública do Estado do Ceará, Juazeiro do Norte, Brazil

²Department of Rheumatology, School of Medicine, Universidade Federal do Cariri, Barbalha, Brazil

³Department of Rheumatology, School of Medicine, Universidade Regional do Cariri, Crato, Brazil

Correspondence: Jucier Gonçalves Júnior, MD.

E-mail: jucierjunior@hotmail.com

Received: July 26, 2024

Accepted: October 29, 2024

Published online: December 12, 2024

Citation: Barros WRG, Gonçalves Júnior J. Deficiency of interleukin-1 receptor antagonist: A systematic review. Arch Rheumatol 2024;39(4):566-578. doi: 10.46497/ArchRheumatol.2024.10882.

This is an open access article under the terms of the Creative Commons Attribution-NonCommercial License, which permits use, distribution and reproduction in any medium, provided the original work is properly cited and is not used for commercial purposes (<http://creativecommons.org/licenses/by-nc/4.0/>).

ABSTRACT

Objectives: The study aimed to conduct a systematic literature review of the epidemiology, pathophysiology, clinical presentation, diagnosis, and treatment of patients with deficiency of the interleukin-1 receptor antagonist (DIRA) and determine the practical contributions that the current scientific literature offers concerning the clinical and epidemiological aspects of DIRA.

Materials and methods: A systematic review of the literature was conducted in the PubMed, Scopus, Web of Science, and the Virtual Health Library databases between January 2009 and June 2024 in accordance with the PRISMA (Preferred Reporting Items for Systematic Reviews and Meta-Analyses) protocol. The following MeSH descriptors were used: "interleukin-1 receptor antagonist deficiency," "epidemiology," "clinical manifestations," "treatment," and "physiopathology."

Results: Of the 3,749 articles, 18 met the eligibility criteria. The findings were divided by heuristic questions into three groups: "epidemiological and genetic aspects of patients with DIRA," "clinical and laboratory characterization in DIRA," and "therapeutic approach to patients with DIRA."

Conclusion: DIRA appears to be more common in males around four years of age. Several IL-1RN mutations were described, varying according to the geographic location. The most common symptoms were fever, followed by osteoarticular manifestations (arthralgia, muscle contracture, fracture, osteolytic lesions, and osteomyelitis), nail changes, pneumonia, venous thrombosis, and, in severe cases, multiple organ failure. There were no specific laboratory markers. Canakinumab was the drug of choice; however, glucocorticoids, riloncept, and anakinra have been used.

Keywords: Clinical practice review, deficiency of interleukin-1 receptor antagonist, epidemiology, interleukin-1.

Mutations in *IL-1RN* result in the partial or complete absence of the IL-1RA (interleukin-1 receptor antagonist) protein, which leads to a significant increase in interleukin (IL)-1 α and IL-1 β activity at the respective receptors. This lack of negative feedback on the IL-1 receptor leads to an acute, severe, and sometimes fatal inflammatory process.^{1,2}

Deficiency of the IL-1RA (DIRA) is caused by biallelic, deleterious loss-of-function mutations in the *IL-1RN* gene, which encodes the IL-1RA, and was first described in 2009.³⁻⁶ Since its first description in 2009, DIRA has been identified as a disease with high morbidity and mortality.¹⁻⁷ The clinical manifestations of DIRA can vary beyond musculoskeletal involvement, with the description of thrombotic events, pulmonary

involvement, and varied skin lesions⁸⁻¹³ on five continents.¹⁻¹⁶ Furthermore, there is a shortage of therapeutic options and their repercussions in the medium and long term.^{1,5,7-21}

Therefore, this study aimed to conduct a systematic literature review of the epidemiology, pathophysiology, clinical presentation, diagnosis, and treatment of patients with DIRA and determine the practical contributions that the current scientific literature offers concerning the clinical and epidemiological aspects of DIRA. Despite technological advances and publications since 2009,¹⁻¹⁰ we hypothesized that there would be a lack of more effective theoretical contributions to the presentation of the epidemiology, pathophysiology, clinical picture, and diagnosis of DIRA.

MATERIALS AND METHODS

Literature review

A qualitative systematic review of the literature was conducted following the PRISMA (Preferred Reporting Items for Systematic Reviews and Meta-Analyses) protocol (Appendix 1). Electronic databases, including PubMed, Scopus, Web of Science, VHL (Virtual Health Library), EMBASE, and Cochrane Library, were searched between January 2009 and June 2024 using the following strategy: #1 “interleukin-1 receptor antagonist deficiency” (MeSH) AND #2 “epidemiology” (MeSH); #1 AND #3 “clinical manifestations” (MeSH); #1 AND #4 “treatment” (MeSH); #1 AND #5 “physiopathology” (MeSH). The year 2009 was chosen as the starting point because it marked the publication of the disease description. The study was carried out with the PICOS framework, where “P” represents patients with DIRA; “I” represents clinical and epidemiological characterization of DIRA; “C” represents healthy control group; and “O” represents the outcomes of the clinical and epidemiology data.

Data collection

Data were collected from December 2023 to July 2024. The articles were preanalyzed based on their titles and abstracts. Two researchers collected data individually, with a third senior researcher being responsible for evaluating discrepancies and doubts. After this selection, each article was read in full, with information about the authors (year of publication), qualitative assessment, country, sex (n), age (mean), age at onset of symptoms, presence of parental consanguinity, type of mutation, gestational age at birth (weeks), presence of delayed growth/development, treatment, and clinical outcomes (Table 1). Table 2 contains information about the clinical and laboratory manifestations of DIRA (rash, fever, nail changes, osteomyelitis, fractures, arthralgia, joint contracture, and pneumonia) and changes in red blood parameters and acute phase proteins.

To analyze the quality of each study, the Study Quality Assessment Tool (<https://www.nhlbi.nih.gov/health-topics/study-quality-assessment-tools>), created by the National Heart, Lung, and

Blood Institute, was used for the convenience of the authors. Case report studies were evaluated using the Quality Assessment Tool for Case Series Studies, and clinical trials were assessed using the Quality Assessment of Controlled Intervention Studies. These quality assessment tools were used to classify studies as “good,” “fair,” or “poor” based on the presence or absence of relevant methodological elements for each type of study.

Eligibility criteria

Articles in Portuguese, English, and Spanish that were original, complete, and addressed the subject of the study were selected. The inclusion criteria considered suitability for this review, availability and transparency of data, and methodological rigor with an emphasis on clinical, comparative, and observational studies. Review or experimental articles, papers with animal models, theses, dissertations, brief comments, editorials, communications, letters to the editor, and papers with a “poor” rating according to the quality assessment tools were excluded.

Ethical statement

Considering that this was a systematic literature review, Resolution 510/16 of the Brazilian National Health Council (CNS, an acronym in Portuguese) exempts it from approval by a Human Research Ethics Committee. This review was registered on the PROSPERO (International Prospective Register of Systematic Reviews) platform under number CRD42024543389.

RESULTS

According to the search strategy, 3,749 articles were identified. Eighteen studies met the eligibility criteria (Figure 1).²² The main results were summarized in Tables 1 and 2 and divided into three groups: “epidemiological and genetic aspects of patients with DIRA”, “clinical and laboratory characterization in DIRA” and “therapeutic approach to patients with DIRA”.

As shown in Table 1, the majority of studies were case reports (94%),^{1,5,7,8-21} followed by clinical trials (14%).⁴ In the quality assessment, more

Table 1. Neonatal characteristics, outcomes, and therapeutic approach of patients with DIRA and quality assessment

Author Country Quality assessment	Sex Age of onset of symptoms	Presence of parental consanguinity	Type of mutation	Gestational age at birth (weeks)	Presence of delayed growth/development	Treatment	Clinical outcomes
Kutukculer et al. ¹ (2019) Türkiye Good	One female Eleven years old	Yes	Homozygous c.85C>T premature stop codon mutation (p.Arg29Ter) in <i>IL-1RN</i> gene	-	Yes	Canakinumab	All patients were alive and healthy
Aksentijevich et al. ⁴ (2009) USA Good	Three female and six male patients Thirteen months Deceased Seven months Deceased Two months Twenty months Four months Nine years old and five days	No - eight patients Yes - one patient	Three mutations in <i>IL-1RN</i> : 175kb homozygous deletion affecting <i>IL-1RN</i> N52KfsX25 mutation (E77X), mutation	34-38	-	Anakinra	Six patients were alive and healthy Three patients died
Reddy et al. ⁵ (2009) USA Good	One male Ten days	Yes	175kb homozygous deletion affecting <i>IL-1RN</i>	33	-	Anakinra	All patients were alive and healthy
Stenerson M et al. ⁷ (2011) USA Fair	One male -	-	Heterozygous mutation for (E77X) and 1 bp deletion in exon 2 of the <i>IL-1RN</i> gene (c.140delC; p.T47TfsX4)	-	Yes	Anakinra	All patients were alive and healthy
Mendonça et al. ⁸ (2017) USA Good	One female Three weeks	No	22.216 kb homozygous deletion affecting <i>IL-1RN</i>	-	Yes	Anakinra	All patients were alive and healthy
Jesus et al. (2011) ⁹ Brazil Good	Two females -	Yes - one patient	Homozygous 15-bp in-frame deletion (c.213_227del AGATGTGGGTACCCAT; p.Asp72_Ile76del)	-	Yes - two patients	Anakinra	All patients were alive and healthy
Minkis et al. ¹⁰ (2012) USA Good	One male Two months	No	175 kb homozygous deletion affecting <i>IL-1RN</i>	31	Yes	Anakinra	All patients were alive and healthy
Rivera-Sepulveda et al. ¹¹ (2021) USA Good	One male Five months	No	175 kb homozygous deletion affecting <i>IL-1RN</i> - 2q (OMIM 612852)	36	Yes	Anakinra	All patients were alive and healthy
Ulusoy et al. ¹² (2015) Türkiye Good	One female One year old	No	p.R26X	38	Yes	Canakinumab	All patients were alive and healthy
Mendonça et al. ¹³ (2020) Brazil Good	One male seven years old	-	Two mutations in <i>IL-1RN</i> : p.Ile71_Pro75del (NM_173842.2; c.211_225del leading to p.I71_P75del) and p.Gln45Ter (NM_173842.2; c.133C>T leading to p.Q45*, rs1019766125)	-	-	Canakinumab	All patients were alive and healthy

Table 1. Continued

Author Country Quality assessment	Sex Age of onset of symptoms	Presence of parental consanguinity	Type of mutation	Gestational age at birth (weeks)	Presence of delayed growth/development	Treatment	Clinical outcomes
Sözert et al. ¹⁴ (2017) Türkiye Good	One male one month	No	One mutation in <i>IL-1RN</i> (c.396delC)	37	Yes	Anakinra	All patients were alive and healthy
Schmellbacher et al. ¹⁵ (2013) USA Fair	One female one week	Yes	175 kb deletion on chromosome 2 q encompassing <i>IL-1RN</i>	37	Yes	Anakinra	All patients were alive and healthy
Brau-Javier et al. ¹⁶ (2012) USA Good	One male two weeks	-	175 kb homozygous deletion affecting <i>IL-1RN</i> and five related adjacent genes (<i>IL-1F9</i> , <i>IL-1F6</i> , <i>IL-1F8</i> , <i>IL-1F5</i>)	-	Yes	Anakinra	All patients were alive and healthy
Sakran et al. ¹⁷ (2013) Israel Fair	One female four months	Yes	Homozygous for the c.160C > T (Q54X) mutation	-	Yes	Anakinra	All patients were alive and healthy
Thacker et al. ¹⁸ (2012) USA Fair	One male seven days	-	-	-	-	Anakinra	All patients were alive and healthy
Ziaee et al. ¹⁹ (2020) Iran Good	One male and one female One month and five days One year old	Yes - two patients	Mutation in <i>IL-1RN</i> (NM_001318914.2; c.54delC;p.Asn18Lysfs*4)	-	Yes	Anakinra	One patient was alive and healthy One patient died
Kuemmerle-Deschner et al. ²⁰ (2020) USA Good	One male Thirteen months	No	-	-	No	Anakinra	All patients were alive and healthy
Altioek et al. ²¹ (2012) USA Good	One female and one male Twenty weeks Gestational age One week	Yes	Mutation in <i>IL-1RN</i> (NM 173842.2 e NP 776214.1)	27 31	Yes	Anakinra	All patients died

DIRA: Deficiency of interleukin-1 receptor antagonist; kb: Kilobase; IL-1: Interleukin 1; USA: United States of America.

Table 2. Clinical and laboratory characterizations of patients with DIRA

Author (year)	Clinical manifestations n/N											Laboratorial changes
	Fever	Skin rashes	Nail changes	Arthralgia	Joint contracture	Osteomyelitis	Bone fracture	Osteolytic lesions	Dyspnea	Pneumonia		
Kutukculer et al. ¹ (2019)	-	-	1/1	1/1	-	-	-	-	-	-	1/1	Microcytic-hypochromic anemia, elevated CRP/ESR
Aksentijevich et al. ⁴ (2009)	-	1/1	-	-	-	1/1	1/1	1/1	1/1	-	-	Microcytic-hypochromic anemia, leukocytosis, elevated CRP/ESR and plateletosis
Stenerson M et al. ⁷ (2011)	1/1	1/1	-	-	-	-	-	1/1	-	-	-	Leukocytosis and elevated CRP/ESR
Mendonca et al. ⁸ (2017)	-	1/1	-	-	1/1	1/1	-	1/1	-	-	-	Microcytic-hypochromic anemia, leukocytosis, plateletosis and elevated CRP/ESR
Jesus et al. ⁹ (2011)	2/2	2/2	-	-	-	2/2	-	1/2	1/2	-	-	Microcytic-hypochromic anemia, leukocytosis, plateletosis and elevated CRP/ESR
Minkis et al. ¹⁰ (2012)	-	-	1/1	-	-	-	-	1/1	-	1/1	-	Microcytic-hypochromic anemia, leukocytosis, monocytosis, plateletosis and elevated CRP/ESR
Rivera-Sepulveda et al. ¹¹ (2021)	1/1	1/1	1/1	-	1/1	1/1	1- Fracture of right femur	-	1/1	-	-	Microcytic-hypochromic anemia, leukocytosis, elevated CRP/ESR
Ulusoy et al. ¹² (2015)	-	1/1	1/1	1/1	1/1	-	-	-	1/1	-	-	Microcytic-hypochromic anemia, elevated immunoglobulins (A, G and M), amyloid substance A, and CRP/ESR
Mendonça et al. ¹³ (2020)	-	1/1	-	1/1	-	1/1	-	-	-	-	-	Leukocytosis, plateletosis, and elevated CRP
Sözzeri et al. ¹⁴ (2017)	1/1	1/1	1/1	1/1	-	-	-	-	-	-	-	Microcytic-hypochromic anemia, leukocytosis, plateletosis, and elevated CRP/ESR
Schnellbacher et al. ¹⁵ (2013)	-	1/1	1/1	1/1	-	1/1	-	-	1/1	-	-	Leukocytosis and elevated CRP/ESR

Table 2. Continued

Author (year)	Clinical manifestations n/N										
	Fever	Skin rashes	Nail changes	Arthralgia	Joint contracture	Osteomyelitis	Bone fracture	Osteolytic lesions	Dyspnea	Pneumonia	Laboratorial changes
Brau-Javier et al. ¹⁶ (2012)	-	1/1	-	-	1/1	1/1	-	1/1	-	-	Microcytic-hypochromic anemia, leukocytosis, plateletosis, and elevated CRP/ESR
Sakran et al. ¹⁷ (2013)	1/1	1/1	1/1	1/1	-	1/1	-	1/1	-	-	Plateletosis and elevated CRP/ESR
Thacker, Binkovit, Thomas ¹⁸ (2012)	1/1	1/1	-	-	-	-	-	1/1	-	-	-
Ziaee et al. ¹⁹ (2020)	-	2/2	1/2	2/2	-	1/2	1- right wrist fracture	-	-	2/2	Microcytic-hypochromic anemia, leukocytosis, and elevated CRP/ESR
Kuemmerle-Deschner et al. ²⁰ (2020)	1/1	-	-	-	-	1/1	-	-	-	-	Elevated CRP/ESR, and amylase elevation
Altioek et al. ²¹ (2012)	-	1/2	-	-	-	2/2	-	-	1/2	1/2	Leukocytosis, neutrophilia, and elevated CRP/ESR

DIRA: Deficiency of interleukin-1 receptor antagonist; CRP: C-reactive protein; ESR: Erythrocyte sedimentation rate; n: Number of patients with the symptom; N: Total sample number.

than half (76.4%) were classified as “good,” with 23.52% classified as “fair” (Table 1).

The highest prevalence was from North American studies (64.7%),^{4,5,7,8,10,11,15,17,18,20,21} followed by those from Türkiye with 17.6% as a European representative,^{1,12,14} Asia (Israel and Iran) with 11.7%,^{16,19} and South America (5.88%) with an article from Brazil⁹ (Table 1).

Among the 18 articles selected, 29 patients with DIRA were confirmed by individual genetic examination or presumed from genetic analysis of the parents in cases of stillbirth.

The majority (58.6%) were male, with a mean age of 4 ± 2.5 months, and an average time since the onset of the disease of 1 month (Table 2).

As shown in Table 1, a good number of patients diagnosed with DIRA had consanguineous parents (34.48%), growth retardation (44.8%), and prematurity (24.13%). It is worth noting that not all articles scored the items presented (Table 1, Figure 2).

The most frequent clinical signs were the presence of pustular lesions on the skin (82.75%), followed by the presence of osteolytic

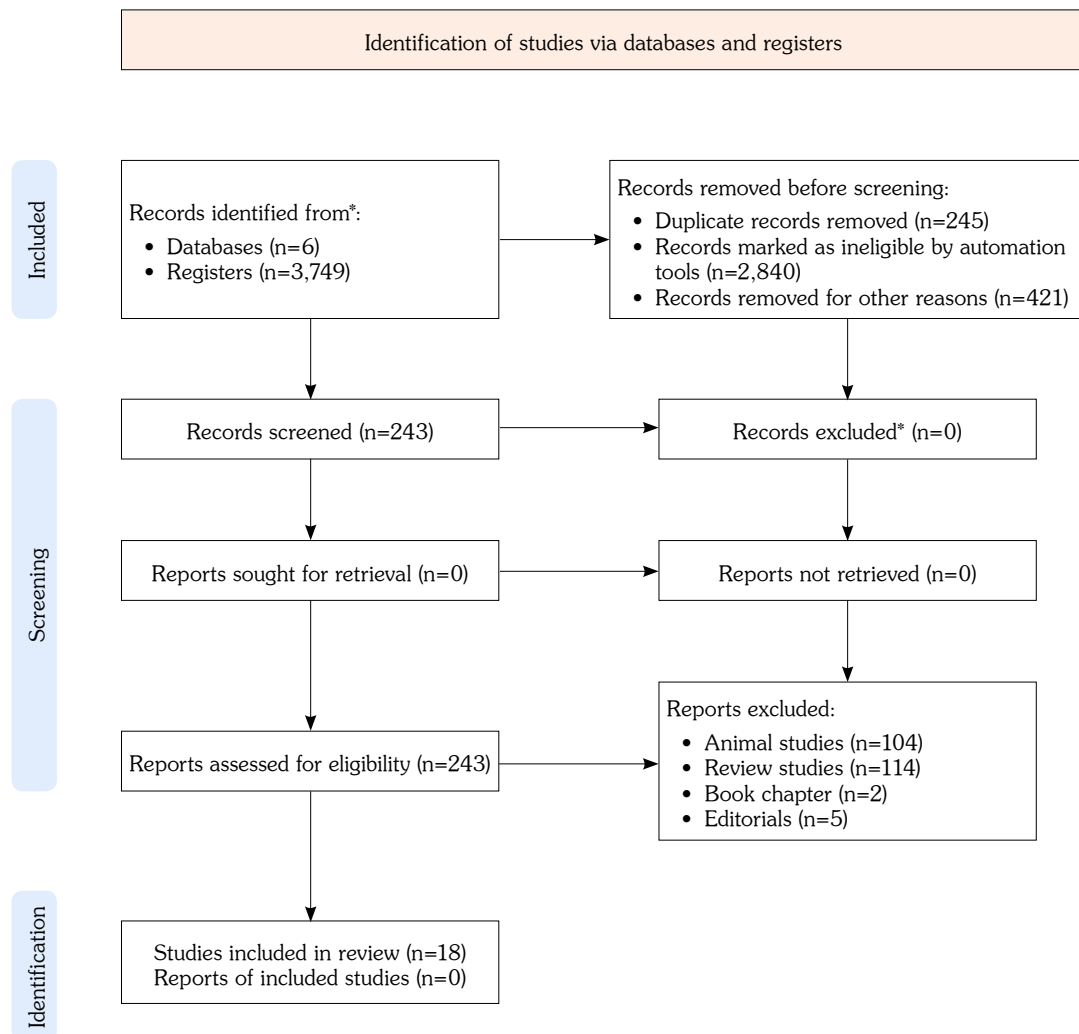


Figure 1. PRISMA 2020 flow diagram for new systematic reviews which included searches of databases and registers only.²²

* Consider, if feasible to do so, reporting the number of records identified from each database or register searched (rather than the total number across all databases/register); ** If automation tools were used, indicate how many records were excluded by a human and how many were excluded by automation tools.

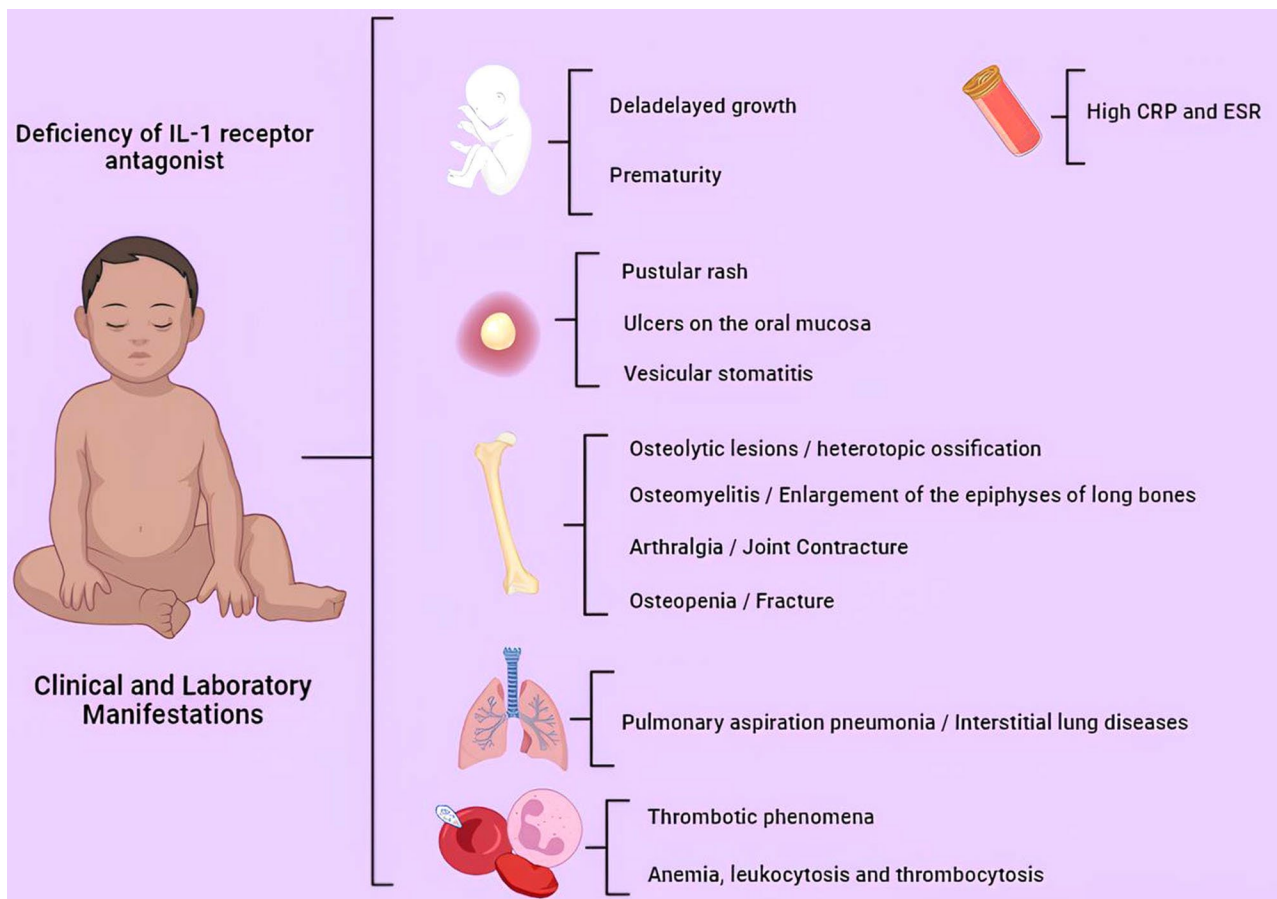


Figure 2. Clinical and laboratory manifestations of deficiency of interleukin-1 receptor antagonist (DIRA).

lesions (55.17%), nail changes (41.37%), osteomyelitis (41.37%), arthralgia (27.58%), fever (27.58%), dyspnea (24.13%), pneumonia (20.68%), joint contracture (13.79%), and bone fracture (10.34%). A percentage (10.34%) of the patients had some episodes of venous thrombosis (Figure 2, Table 2).

Of the patients who underwent laboratory tests, 57.17% showed increased inflammatory activity (ESR [erythrocyte sedimentation rate] and CRP [C-reactive protein]); a proportion also had leukocytosis (48.27%) and hypochromic microcytic anemia (37.93%), as provided in Table 2 and Figure 2.

Regarding the treatment, the majority (58.62%) used anakinra, an anti-IL1 agent, and a minority (10.34%) used canakinumab, an IL-1 β blocker, as shown in Table 1.

DISCUSSION

Epidemiological and genetic aspects of patients with DIRA

Some gene loci have been associated with DIRA depending on the geographic location. In the Americas, the 175 kb mutation (located in 2q13) was evidenced in Puerto Rican patients with DIRA, with an allele frequency of 1.3% and an incidence of 1 in every 6,300 births.¹⁶ This mutation involves the *IL-1RN* gene and appears to be a pathological variable in the involvement of this gene in the etiopathogenesis of DIRA.¹⁶ In 2009, Aksentijevich et al.⁴ described more Puerto Rican patients who were homozygous for mutations in the *IL-1RN* gene or had parents who were, respectively, heterozygous for these mutations.

In Brazil, the first patients recognized with DIRA were two unrelated children carrying the same 15 bp homozygous deletion (in-frame) in the *IL-1RN* gene (p.Asp72_Ile76del).¹³ The p.Q45* mutation (rs1019766125) is present in all Brazilian patients with previously described DIRA.^{9,13} It is a new mutation that affects the *IL-1RN* gene.^{9,13}

Studies in Asia^{8,16,19} showed a homozygous mutation for c.160C<T (Q54X) evidenced in an Arab-Lebanese patient. The same mutation was observed in two unrelated Lebanese families, which may suggest a founder effect at this locus.¹⁷ Another mutation (N52KfsX25) was also observed in Lebanese families, with an estimated allele frequency of 0.2%.⁴ A 16-year-old male of Iranian-Persian origin with consanguineous parents and heterozygous carriers of the mutation (L1RN NM_001318914.2:c.54delC;p.Asn18Lysfs*4) also presented with DIRA.^{17,19} The homozygous deletion of 22,216 bp covering the first four exons of *IL-1RN* was described by Mendonça et al.¹³ in an Indian girl diagnosed with DIRA born to healthy, unrelated parents. This mutation is likely a founder mutation in the Indian region.⁸

In Europe, Türkiye has a large number of descriptions of *IL-1RN* mutations.^{1,12,21} Altıok et al.²¹ reported two brothers with a new mutation (Q119X). One of the brothers presented with early intrauterine onset and premature death after multiple organ involvement. In 2015, the mutation p.R26X was described by Ulusoy et al.¹² in a patient without pustular lesions or joint pain at an age of 12 years of age with a healthy neonatal period.

A single homozygous deletion of the C nucleotide at nucleotide position 396 (c.396delC) in the *IL-1RN* gene was found in a third Turkish patient in 2017, causing a frameshift mutation and, as a result, *IL-1RN* stop codon at position c.534. disappeared, and the respective protein became nonfunctional.¹⁴

Kutukçuler et al.¹ described the homozygous premature stop codon mutation c.85C>T (p.Arg29Ter) in the *IL-1RN* gene, confirmed by Sanger sequencing, in a girl with consanguineous parents and the symptoms of nail psoriasis, inflammatory arthritis, and onychomycosis. This new *IL-1RN* mutation produced an anomalous

protein that could not bind to the IL-1 receptor and, therefore, had a loss of function. In 2009, Aksentijevich et al.⁴ described nine patients with DIRA, five of whom were from three unrelated Dutch families and exhibited a nucleotide nonsense mutation affecting amino acid position 77 (E77X), resulting in a truncated IL-1RA protein that was not secreted, suggesting a founder effect. The patient described by Stenerson et al.⁷ in 2011 was heterozygous for this “Dutch” E77X mutation. However, a new 1 bp deletion was discovered in exon 2 of the *IL-1RN* gene (c.140delC; p.T47TfsX4).^{4,7}

Regarding the studies mapping the epidemiological profile and mutations of patients with DIRA, some limitations deserve to be highlighted: (i) the small sample size, (ii) the failure to map all clinical aspects involved in DIRA, (iii) the cross-sectional and retrospective nature of the studies, and (iv) the lack of homogenization in genetic evaluation methods across countries.^{4,7,8,12,14,16,19}

Clinical and laboratory characterization in DIRA

According to the literature, the majority of patients with DIRA are premature with fetal distress at birth and intrauterine growth restriction.^{14,15} Stenerson et al.⁷ described polyhydramnios as an associated manifestation. IL-1 is believed to play an important role in the process of prematurity, as high levels are associated with the onset of labor prematurely.¹¹

In the first two and a half weeks of life, pustular rashes on the face, ulcers on the oral mucosa, vesicular stomatitis, and osteoarticular conditions are more prevalent.^{11,14,15} These findings are similar to those found in the present systematic review.

Among the musculoskeletal changes, we can mention periosteal reaction in long bones with enlargement of the extremities (e.g., clavicle and ribs), fused cervical vertebrae, periostitis of anterior ribs, erosions, osteopenia, multifocal lytic changes, and heterotopic ossification.^{16,18}

Finally, fever,^{7,13} hepatosplenomegaly, thrombotic phenomena (e.g., iliac vein thrombosis and central nervous system vasculitis),^{12,15} ascites,⁷ and pulmonary involvement (e.g., apnea, pulmonary aspiration pneumonia, and interstitial

lung diseases)¹¹ have also been described in the literature, but to a lesser extent. This corroborates the findings of the present systematic review.

There was no mapping of specific inflammatory markers in the context of DIRA. However, elevated CRP and ESR, normocytic normochromic anemia, and leukocytosis may occur, being indirect markers of increased IL-1.⁷

However, an important limitation of the studies analyzed is the small sample size, the lack of information on gestational age, obstetric history, and fetal distress, as well as the lack of a complete mapping of clinical manifestations and further investigation with other inflammatory markers, presence of autoantibodies, and imaging tests.^{4,21}

Therapeutic approach to patients with DIRA

Due to the severity of the symptoms and the risk of death in the first months of life, treatment for DIRA must be instituted early. There are three alternatives: anakinra, riloncept, and canakinumab.^{1,9}

Anakinra is a recombinant human IL-1RA that blocks the proinflammatory effects of IL-1 β , which is administered subcutaneously at an initial dose of 1 mg/kg/day. Studies, although scarce, demonstrate complete remission.^{1,9} Therapy can be instituted for life, and some studies have demonstrated that attempts to withdraw the medication¹⁵ involved flares of the disease.

Riloncept is a recombinant fusion protein that has a longer half-life and binds to both IL-1 α and IL-1 β . Although Anakinra was initially used in all patients with DIRA to control the disease, this drug can be used to maintain its remission.²

Canakinumab is a human monoclonal antibody to IL-1 β and has a long half-life. In some patients, it has been shown to not completely block bone inflammation.²

However, the efficacy and safety of long-term anakinra treatment remain under investigation. It has not been established whether longer-acting IL-1 inhibitors, such as canakinumab, are as effective as anakinra in treating patients with autoinflammatory diseases.¹⁵ Nevertheless, the literature shows that DIRA patients were in clinical remission after undergoing treatment with

resolution of bone lesions and nail anomalies, in addition to the normalization of inflammatory activity tests and red blood changes.^{11,17}

Glucocorticoids can be used as adjuvant therapy, with an improvement of the initial condition and without complete response and exposure to long-term side effects,⁸ such as elevated blood pressure, dysglycemia, osteopenia/osteoporosis, healing defects, and infections.¹ Antimicrobial therapy with beta-lactams is prescribed in patients with DIRA at the onset of the condition, mainly because the disorder mimics bacterial infections.²

The main biases to be pointed out in these studies^{1,2,11,15,17} are the retrospective nature and insufficient sampling. These limitations make it difficult to generalize and map the safety and efficacy of interventions and to compare them in the long term.

As limitations of the present study, the following should be mentioned: lack of more robust studies,^{1,5,7,8-21} lack of information such as clinical and epidemiological mapping of patients with DIRA,^{1,4,5,7,8-21} the prevalence of case reports in the sample,^{1,5,7,8-21} which does not allow adequate generalizations, and inability to perform a meta-analysis due to the previous items. Moreover, the studies assessing some DIRA aspects (epidemiology, physiopathology, and treatment) had some biases: collection bias due to the absence of genetic mapping in all cases^{1,5,7,8-21} and recall bias due to the retrospective nature of several of the studies.^{1,5,7,8-21} These biases limited our analysis and may have underestimated our results.

In conclusion, DIRA is an autosomal recessive disease with cutaneous and osteoarticular manifestations that are more prevalent in the first months of life. There are no specific laboratory markers, and the diagnosis is made through genetic testing. However, mutations associated with *IL1RN* have not yet been fully mapped. Due to the relatively rare description, the severity profile, the few therapeutic options, and the poor prognosis without early intervention, DIRA warrants the attention of immunologists and rheumatologists. Given the quality of the current evidence, there is an urgent need for joint mobilization and the conduction of multicenter studies with robust sampling and design to map

out the etiopathogenesis of the disease, the long-term use of the therapeutic options, and the safety profiles.

Data Sharing Statement: The data that support the findings of this study are available from the corresponding author upon reasonable request.

Author Contributions: The authors contributed equally to the design, collection, analysis, interpretation of data, and final verification of the data paper.

Conflict of Interest: The authors declared no conflicts of interest with respect to the authorship and/or publication of this article.

Funding: The authors received no financial support for the research and/or authorship of this article.

REFERENCES

1. Kutukculer N, Puel A, Eren Akarcan S, Moriya K, Edeer Karaca N, Migaud M, et al. Deficiency of interleukin-1 receptor antagonist: A case with late onset severe inflammatory arthritis, nail psoriasis with onychomycosis and well responsive to Adalimumab therapy. *Case Reports Immunol* 2019;2019:1902817. doi: 10.1155/2019/1902817.
2. Romano M, Arici ZS, Piskin D, Alehashemi S, Aletaha D, Barron K, et al. The 2021 EULAR/American College of Rheumatology points to consider for diagnosis, management and monitoring of the interleukin-1 mediated autoinflammatory diseases: Cryopyrin-associated periodic syndromes, tumour necrosis factor receptor-associated periodic syndrome, Mevalonate kinase deficiency, and deficiency of the interleukin-1 receptor antagonist. *Arthritis Rheumatol* 2022;74:1102-21. doi: 10.1002/art.42139.
3. Dinarello CA. Interleukin-1 β and the autoinflammatory diseases. *N Engl J Med* 2009;360:2467-70. doi: 10.1056/NEJMe0811014.
4. Aksentijevich I, Masters SL, Ferguson PJ, Dancey P, Frenkel J, van Royen-Kerkhoff A, et al. An autoinflammatory disease with deficiency of the interleukin-1-receptor antagonist. *N Engl J Med* 2009;360:2426-37. doi: 10.1056/NEJMoa0807865.
5. Reddy S, Jia S, Geoffrey R, Lorier R, Suchi M, Broeckel U, et al. An autoinflammatory disease due to homozygous deletion of the IL1RN locus. *N Engl J Med* 2009;360:2438-44. doi: 10.1056/NEJMoa0809568.
6. Garg M, de Jesus AA, Chapelle D, Dancey P, Herzog R, Rivas-Chacon R, et al. Rilonacept maintains long-term inflammatory remission in patients with deficiency of the IL-1 receptor antagonist. *JCI Insight* 2017;2:e94838. doi: 10.1172/jci.insight.94838.
7. Stenerson M, Dufendach K, Aksentijevich I, Brady J, Austin J, Reed AM. The first reported case of compound heterozygous IL1RN mutations causing deficiency of the interleukin-1 receptor antagonist. *Arthritis Rheum* 2011;63:4018-22. doi: 10.1002/art.30565.
8. Mendonca LO, Malle L, Donovan FX, Chandrasekharappa SC, Montealegre Sanchez GA, Garg M, et al. Deficiency of Interleukin-1 Receptor Antagonist (DIRA): Report of the first Indian patient and a novel deletion affecting IL1RN. *J Clin Immunol* 2017;37:445-51. doi: 10.1007/s10875-017-0399-1.
9. Jesus AA, Osman M, Silva CA, Kim PW, Pham TH, Gadina M, et al. A novel mutation of IL1RN in the deficiency of interleukin-1 receptor antagonist syndrome: Description of two unrelated cases from Brazil. *Arthritis Rheum* 2011;63:4007-17. doi: 10.1002/art.30588.
10. Minkis K, Aksentijevich I, Goldbach-Mansky R, Magro C, Scott R, Davis JG, et al. Interleukin 1 receptor antagonist deficiency presenting as infantile pustulosis mimicking infantile pustular psoriasis. *Arch Dermatol* 2012;148:747-52. doi: 10.1001/archdermatol.2011.3208.
11. Rivera-Sepulveda A, Colón-Fontáñez F, López M, Puig-Ramos G. Deficiency of interleukin-1 receptor antagonist: New genetic autoinflammatory disease as a diagnostic challenge for pediatricians. *J Pediatr Genet* 2021;12:227-32. doi: 10.1055/s-0041-1724113.
12. Ulusoy E, Karaca NE, El-Shanti H, Kilicoglu E, Aksu G, Kutukculer N. Interleukin-1 receptor antagonist deficiency with a novel mutation; Late onset and successful treatment with canakinumab: A case report. *J Med Case Rep* 2015;9:145. doi: 10.1186/s13256-015-0618-4.
13. Mendonça LO, Grossi A, Caroli F, de Oliveira RA, Kalil J, Castro FFM, et al. A case report of a novel compound heterozygous mutation in a Brazilian patient with Deficiency of Interleukin-1 Receptor Antagonist (DIRA). *Pediatr Rheumatol Online J* 2020;18:67. doi: 10.1186/s12969-020-00454-5.
14. Sözeri B, Gerçeker-Türk B, Yıldız-Atıkan B, Mir S, Berdeli A. A novel mutation of Interleukin-1 Receptor Antagonist (IL1RN) in a DIRA patient from Turkey: Diagnosis and treatment. *Turk J Pediatr* 2018;60:588-92. doi: 10.24953/turkijped.2018.05.020.
15. Schnellbacher C, Ciocca G, Menendez R, Aksentijevich I, Goldbach-Mansky R, Duarte AM, et al. Deficiency of interleukin-1 receptor antagonist responsive to anakinra. *Pediatr Dermatol* 2013;30:758-60. doi: 10.1111/j.1525-1470.2012.01725.x.
16. Brau-Javier CN, Gonzales-Chavez J, Toro JR. Chronic cutaneous pustulosis due to a 175-kb deletion on chromosome 2q13: Excellent response to anakinra. *Arch Dermatol* 2012;148:301-4. doi: 10.1001/archdermatol.2011.2857.
17. Sakran W, Shalev SA, Sakran W, Shalev SA, El-Shanti H, Uziel Y, et al. Chronic recurrent multifocal osteomyelitis and deficiency of interleukin-1-receptor antagonist. *Pediatr Infect Dis J* 2013;32:94. doi: 10.1097/INF.0b013e3182700cc1.

18. Thacker PG, Binkovitz LA, Thomas KB. Deficiency of interleukin-1-receptor antagonist syndrome: A rare auto-inflammatory condition that mimics multiple classic radiographic findings. *Pediatr Radiol* 2012;42:495-8. doi: 10.1007/s00247-011-2208-y.
19. Ziaee V, Youssefian L, Faghankhani M, Jazayeri A, Saeidian AH, Vahidnezhad H, et al. Homozygous IL1RN mutation in siblings with Deficiency of Interleukin-1 Receptor Antagonist (DIRA). *J Clin Immunol* 2020;40:637-42. doi: 10.1007/s10875-020-00767-w.
20. Kuemmerle-Deschner JB, Welzel T, Hoertnagel K, Tsiflikas I, Hospach A, Liu X, et al. New variant in the IL1RN-gene (DIRA) associated with late-onset, CRMO-like presentation. *Rheumatology (Oxford)* 2020;59:3259-63. doi: 10.1093/rheumatology/keaa119.
21. Altioek E, Aksoy F, Perk Y, Taylan F, Kim PW, Ilikkan B, et al. A novel mutation in the interleukin-1 receptor antagonist associated with intrauterine disease onset. *Clin Immunol* 2012;145:77-81. doi: 10.1016/j.clim.2012.08.003.
22. Page MJ, McKenzie JE, Bossuyt PM, Boutron I, Hoffmann TC, Mulrow CD, et al. The PRISMA 2020 statement: an updated guideline for reporting systematic reviews. *BMJ* 2021;372:n71. doi: 10.1136/bmj.n71.

APPENDIX 1- Research protocol

- **Month of collection:** December 2023 to July 2024
 - **Period of publication of the Periodicals:** January 1, 2009 and June 31, 2024

- **MeSH terms:**

- #1 "interleukin-1 receptor antagonist deficiency";
 - #2 "epidemiology";
 - #3 "clinical manifestations";
 - #4 "treatment";
 - #5 "physiopathology";
-

1 Virtual Health Library (VHL)

(N° of articles found: 901 | N° of articles selected: 6 | N° of articles excluded: 895 | N° of articles repeated: 0)

- #1 AND #2
- #1 AND #3
- #1 AND #4
- #1 AND #5

2 PubMed

(N° of articles found: 47 | N° of articles selected: 4 | N° of articles excluded: 43)

- #1 AND #2
- #1 AND #3
- #1 AND #4
- #1 AND #5

3 Cochrane Library

(N° of articles found: 11 | N° of articles selected: 0 | N° of articles excluded: 11)

- #1 AND #2
- #1 AND #3
- #1 AND #4
- #1 AND #5

4 Scopus

(N° of articles found: 758 | N° of articles selected: 4 | N° of articles excluded: 227)

- #1 AND #2
- #1 AND #3
- #1 AND #4
- #1 AND #5

5 Web of Science

(N° of articles found: 1090 | N° of articles selected: 3 | N° of articles excluded: 1087)

- #1 AND #2
- #1 AND #3
- #1 AND #4
- #1 AND #5

6 EMBASE

(N° of articles found: 942 | N° of articles selected: 1 | N° of articles excluded: 941)

- #1 AND #2
 - #1 AND #3
 - #1 AND #4
 - #1 AND #5
-