


## Elastosonography and electrodiagnosis in relation to symptomatic and functional grading of carpal tunnel syndrome

Marwa Yahia , Ahmed El Shambaky , Doaa Lasheen 

Department of Rheumatology, Rehabilitation and Physical Medicine, Faculty of Medicine, Benha University, Benha, Egypt

### ABSTRACT

**Objectives:** This study focused on the symptomatic and the functional evaluation in correlations to median nerve elasticity, its ultrasound parameters, and the electrodiagnostic grading of primary carpal tunnel syndrome (CTS) patients.

**Patients and methods:** In the case-control study, 100 wrists of 57 CTS patients (54 females, 3 males; mean age: 39±9.8 years; range, 20 to 60 years) clinically diagnosed according to the American Academy of Neurology Clinical Diagnostic Criteria were evaluated between December 2019 and December 2020. The control group included 110 nondiseased wrists of 55 sex- and age-matched healthy subjects (males 7, females 48; mean age: 35.7±10.3 years; range 20 to 58 years). Functional assessment using Hi-Ob-Db clinical scale, electrodiagnosis, ultrasonographic screening, and elasticity evaluation were done for all patients.

**Results:** CTS patients had an increased stiffness of the median nerve compared to controls. Functional stages were positively correlated with the ultrasonographic parameters and the electrodiagnostic stages of CTS. The elastogram of clinically diagnosed patients was revealed more stiffness of the MN, with negative electrodiagnosis results.

**Conclusion:** Clinically diagnosed CTS could be missed by the electrodiagnosis but then properly figured by ultrasonography and potentially graded by sonoelastography. Sonoelastography may be an effective method for early diagnosis and appropriate grading of CTS.

**Keywords:** Carpal tunnel syndrome, elasticity, electrodiagnosis, elastosonography, functional assessment.

Carpal tunnel syndrome (CTS) is one of the most prevalent focal demyelinating neuropathies rising from the median nerve (MN) entrapment at the wrist. Its clinical presentation varies between pain, numbness, tingling, and, lately, muscle weakness and decreasing hand dexterity function.<sup>1</sup> Although the CTS prevalence rate is reported to be 0.6 to 5.8% of the general population, majority of cases are undiagnosed. Identification of CTS depends on the characteristic clinical picture and is assured by the electrodiagnostic examination (EDX).<sup>2</sup>

Carpal tunnel syndrome has its eminent clinical and electrodiagnostic criteria and ultrasonographic characteristics; however, it is still considered a frequent cause of morbidity with a significant occupational and functional burden. In the last years, research pointed to the role of elastography in evaluating the nerve fibers in various conditions, which highlighted the potential importance in early diagnosis of various pathologies.<sup>3</sup>

Elastography is an imaging modality that maps tissue stiffness. It is an emerging tool in

**Received:** December 03, 2022 **Accepted:** March 05, 2023 **Published online:** August 23, 2023

**Correspondence:** Marwa Yahia, MD. Department of Rheumatology, Rehabilitation and Physical Medicine, Faculty of Medicine, Benha University, Benha, Egypt.  
E-mail: marwayahiamlm@gmail.com

### Citation:

Yahia M, Shambaky AE, Lasheen D. Elastosonography and electrodiagnosis in relation to symptomatic and functional grading of carpal tunnel syndrome. Arch Rheumatol 2023;38(x):i-xiv.

©2023 Turkish League Against Rheumatism. All rights reserved.

This is an open access article under the terms of the Creative Commons Attribution-NonCommercial License, which permits use, distribution and reproduction in any medium, provided the original work is properly cited and is not used for commercial purposes (<http://creativecommons.org/licenses/by-nc/4.0/>).

the musculoskeletal system evaluation, including muscles, tendons, ligaments, and nerves. This technique adds information about the elastic properties of the scanned tissues. This improves the conventional ultrasound evaluation of the morphological and vascular information obtained from B-mode ultrasound and Doppler imaging.<sup>4</sup>

In the last decade, the evaluation of the MN elasticity in CTS patients was the aim of the research. With different targeting CTS cases and using either static strain elastography (tissue compression produces strain)<sup>5</sup> or shear wave elastography (focused acoustic radiation force from a linear ultrasound array),<sup>6</sup> MN stiffness was reported, and its elastoscan determined the early pathophysiological changes that are caused by CTS.<sup>7-10</sup>

This study is an extension of the study by Lasheen et al.,<sup>11</sup> which aimed to compare CTS patients and healthy volunteers regarding the ultrasound and sonoelastography (SE) of the MN at the wrist and the later correlation to nerve conduction study (NCS) results and included increased stiffness of MN affected by CTS with positive correlations with NCSs. In this paper, we focused on the symptomatic and the functional evaluation in correlation to MN elasticity, its ultrasound parameters, and the electrodiagnostic grading of primary CTS patients. The study highlighted the potential role of elastography modality in the early diagnosis and prognosis of CTS.

## PATIENTS AND METHODS

The case-control study was conducted at the Faculty of Medicine, Benha University, Rheumatology, Rehabilitation, and Physical Medicine Department's electromyography (EMG) laboratory and musculoskeletal ultrasound unit, and the data of 100 wrists of 57 CTS patients (54 females, 3 males; mean age:  $39 \pm 9.8$  years; range, 20 to 60 years) clinically diagnosed according to the American Academy of Neurology clinical diagnostic criteria of CTS were analyzed. Patients below the age of 20 and above 60 years, those who had a history of neurological or chronic disorders other than CTS, those who had previous corticosteroids injection or operations for CTS treatment, and patients with pathological

or anatomical abnormalities like lipomas or bifid MN discovered by ultrasound were excluded from the study. One hundred ten nondiseased wrists of 55 sex- and age-matched healthy volunteers (males 7, females 48; mean age:  $35.7 \pm 10.3$  years; range 20 to 58 years) were included in the control group. They were recruited from hospital personnel and relatives of other patients.

All patients were subjected to a complete history taking and clinical examination, including provocative tests. Radiological examination, laboratory assessment, and functional assessment applying the historical-objective-distribution-based (Hi-Ob-Db) scale were done to classify the clinical severity of CTS. The patient group was classified into five stages according to the Hi-Ob-Db clinical scale. Each stage has a possible additional combination of pain. The pain was assessed by the patients answering yes or no. The Hi-Ob-Db score was indicated by the numbers 1-5: stage 0, no symptoms suggestive of CTS; Stage 1, only nocturnal paresthesia independent from the distribution and absence of deficit at abductor pollicis brevis (APB); Stage 2, nocturnal and diurnal paresthesia independent from the distribution and absence of deficit at APB; Stage 3, glove distribution of paresthesia and presence of deficit at APB but no plegia; Stage 4, MN distribution of paresthesia and presence of a deficit at APB but no plegia; and Stage 5, plegia of APB.<sup>12</sup>

Consequently, the patients underwent EDX according to the protocol recommended by the American Association of Electrodiagnostic Medicine in 2002<sup>13</sup> using a Neurowerk EMG unit with a four-channel evoked potential/EMG measuring system (SIGMA Medizin-Technik GmbH, Gelenau/Erzgebirge, Germany), and the CTS was classified according to Bland's<sup>14</sup> classification system for CTS into six grades.

Finally, participants underwent a neuromuscular ultrasound evaluation using a linear high-frequency 6-15 MHz probe with an ultrasound machine (LOGIQ™ P9; GE Healthcare Life Sciences, Seoul, South Korea) equipped with elastography software for each wrist, MN cross-sectional areas (CSA) at the wrist, wrist/forearm ratio (WFR) and flattening ratio were obtained along with a subjective assessment of the MN echogenicity, mobility, and vascularity. Sonoelastographic evaluation of the MN was assumed fitting to the

procedure of Tatar et al.<sup>15</sup> Additionally, the ratio between MN elasticity at the carpal tunnel inlet and at 4 cm proximal to the carpal tunnel inlet (MED/MEP ratio) was assessed in all participants.

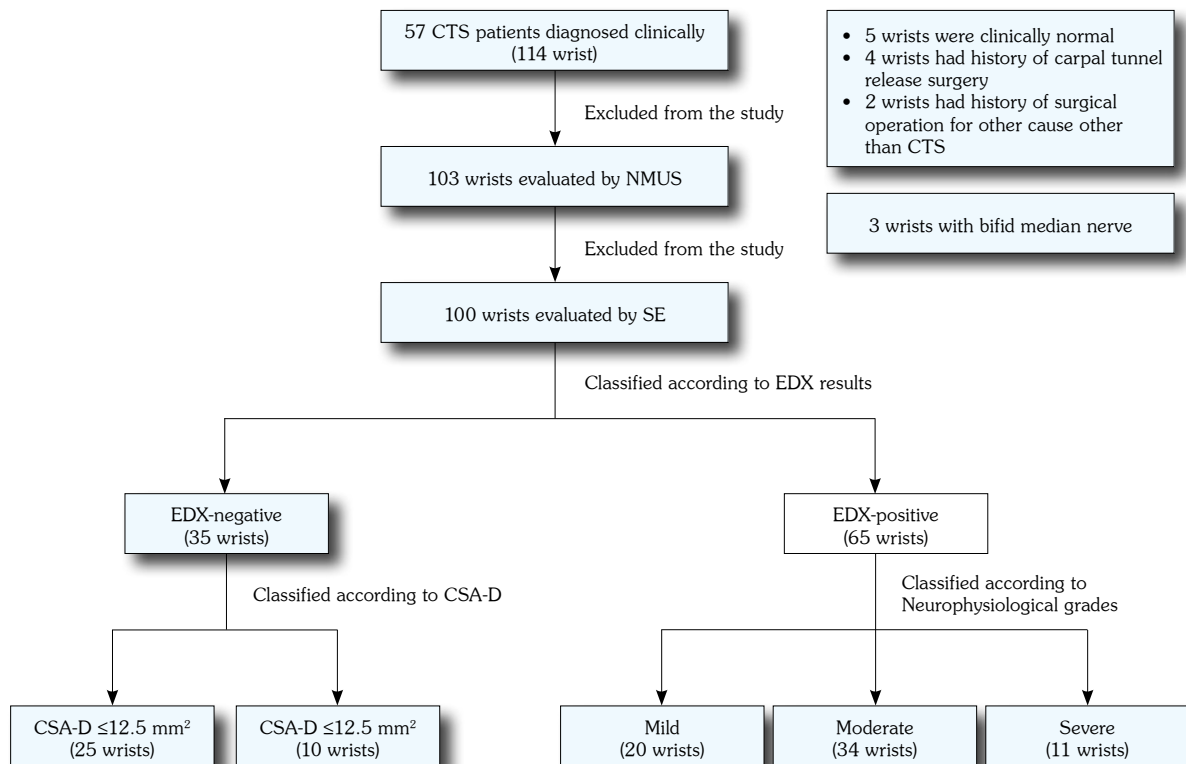
Strain elastography was done by light compressions applied by the ultrasound probe. The relative stiffness of the tissues was designated as a color code within the region of interest (ROI) and varied from red (soft) to blue (hard). Medium elasticity was shown by green and yellow colors. Elliptical ROIs were drawn within the MN and again within the flexor carpi radialis, which was chosen as a reference tissue as it is outside the carpal tunnel. The elastic ratio (ER) is the ratio of strain distribution in the two selected ROI. Measurements were repeated three times, and the average strain ratio was recorded.

### Statistical analysis

Power analysis was performed using G\*Power version 3.1.9.7 (Heinrich-Heine-Universität Düsseldorf, Düsseldorf, Germany), with  $p=95\%$  and  $\alpha=0.05$ .<sup>16</sup> The total amount of participants

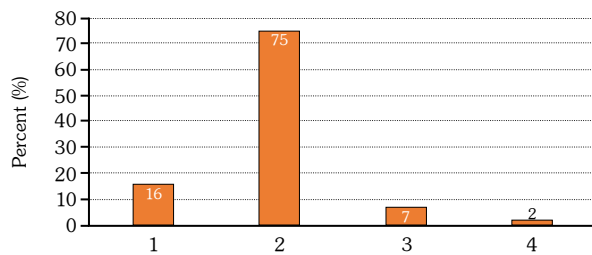
required was at least 94 (divided into two groups, 48 patients and 48 controls), where the effect size was 0.75 (calculated from a previous study by Ibrahim and Heba<sup>17</sup> and the dropout rate applied was 15%.

The collected data were analyzed using the IBM SPSS version 25.0 (IBM Corp., Armonk, NY, USA). The Kolmogorov-Smirnov test was done to evaluate the normality of data. The mean  $\pm$  standard were used for parametric numerical data, while median and range was used for nonparametric numerical data. Nonnumerical data were expressed as frequency and percentage. Student's t-test was used to assess the difference in the neuromuscular ultrasound (NMUS) and elastography parameters' mean between CTS patients and healthy controls. For the comparison of more than two groups' means, one-way analysis of variance was used. The Mann-Whitney U test was used to assess the statistical significance of the difference of a nonparametric variable between two study groups. The Kruskal-Wallis was used to assess the statistical significance of



**Figure 1.** Flow diagram of patients included in the study.

CTS: Carpal tunnel syndrome; NMUS: Neuromuscular ultrasound; SE: Sonoelastography; EDX: Electro diagnostic studies; CSA-D: Cross sectional area distal at carpal tunnel.



**Figure 2.** Hi-Ob-Db scale among studied wrists.

Hi-Ob-Db: Historical-objective-distribution-based

the difference between more than two study group nonparametric variables. The chi-square test was used to examine the relationship between two qualitative variables. Fisher exact test was used to examine the relationship between two qualitative variables when the expected count was  $<5$  in more than 20% of cells. The correlation coefficient defines the strength and direction of the linear relationship between two variables. A  $p$ -value  $<0.05$  was considered statistically significant, whereas a  $p$ -value  $<0.001$  was considered highly significant.

## RESULTS

Fourteen wrists of 14 patients were excluded from the study as five wrists were clinically

normal, four wrists had previous operations for MN release, two wrists had previous operations, and three wrists with bifid MNs.

Among the 57 CTS patients, the reversed Phalen test was positive in all wrists, while the Tinel sign was positive in 76 (76%) wrists (Figure 1). CTS was proved by EDX in 65 wrists (20 mild, 34 moderate, and 11 severe stages). Of the other clinically diagnosed 35 wrists, only 10 wrists had MNs with a CSA  $>12$  mm<sup>2</sup> by ultrasound evaluation that fitted the cut section point of CTS diagnosis (Figure 2).

According to the Hi-Ob-Db scale, 16 (16%) wrists were Stage 1 (8% having pain and 8% free of pain), 75 were Stage 2, seven wrists were Stage 3, and two wrists were Stage 4. No wrist was fit for Stage 5 (Figure 2).

Concerning the clinical and functional assessments among the CTS subgroups, there was a significant difference between the EDX severity grades regarding the positive Tinel's sign and the Hi-Ob-Db scale functional stages being more prominent in moderate and severe stages (Table 1).

Comparisons of the NMUS and sonoelastographic findings among the CTS groups regarding EDX results were done and

**Table 1.** Comparisons among the studied CTS sub-groups regarding clinical and functional assessments

	CTS sub-groups according to EDX results								<i>p</i>
	Normal (n=35)		Mild (n=20)		Moderate (n=34)		Severe (n=11)		
	n	%	n	%	n	%	n	%	
Positive Phalen's maneuver									
No	0	0	0	0	0	0	0	0	-
Yes	35	100	20	100	34	100	11	100	
Positive Tinel's test									
No	16	45.7	3	15	4	11.8	1	9.1	0.004*
Yes	19	54.3	17	85	30	88.2	10	90.9	
Hi-Ob-Db scale stages									
1	11	31.4	3	15	2	5.9	0	0	$<0.001^{**}$
2	24	68.6	17	85	28	82.4	6	54.5	
3	0	0	0	0	3	8.8	4	36.4	
4	0	0	0	0	1	2.9	1	9.1	

CTS: Carpal tunnel syndrome; EDX: Electro diagnostic examination; Hi-Ob-Db: Historical-objective-distribution-based; *p*: Probability value; \* $p<0.05$ = significant,  $p>0.05$ = insignificant; \*\*  $p<0.001$ = highly significant.

**Table 2.** Comparisons of the NMUS and sonoelastographic findings among the CTS groups regarding EDX results

Parameters	CTS with EDX-normal (n=35)					CTS with EDX-positive (n=65)					p
	n	%	Mean±SD	Median	Range	n	%	Mean±SD	Median	Range	
CSA-D			16.9±5.5					9±1.9			<0.001**
Wrist/forearm ratio				1.42	0.87-2.50				2.33	1.25-5.66	<0.001**
Echogenicity											
Normal	18	51.4				11	16.9				
Slightly reduced	16	45.7				38	58.5				<0.001**
Reduced	1	2.9				16	24.6				
Mobility											
1	4	11.4				18	27.7				
2	16	45.7				32	49.2				<0.001**
3	15	42.9				15	23.1				
Vascularity											
Normal	35	100				51	78.5				-
Slightly increased	0	0				14	21.5				
Flattening ratio			2.6±0.9					3.1±0.7			0.001**
Elastic ratio			1.5±0.5					1.7±0.6			0.044*
MED/MEP ratio				1.81	0.5-3.2				1.53	0.5-5.3	0.319

NMUS: Neuromuscular ultrasound; CTS: Carpal tunnel syndrome; EDX: Electrodiagnostic examination; SD: Standard deviation; CSA-D: Cross sectional area distal at carpal tunnel; MED/MEP ratio: MN elasticity between distal and proximal, p: Probability value, \* p<0.05= significant; p>0.05= insignificant; \*\* p<0.001= highly significant.

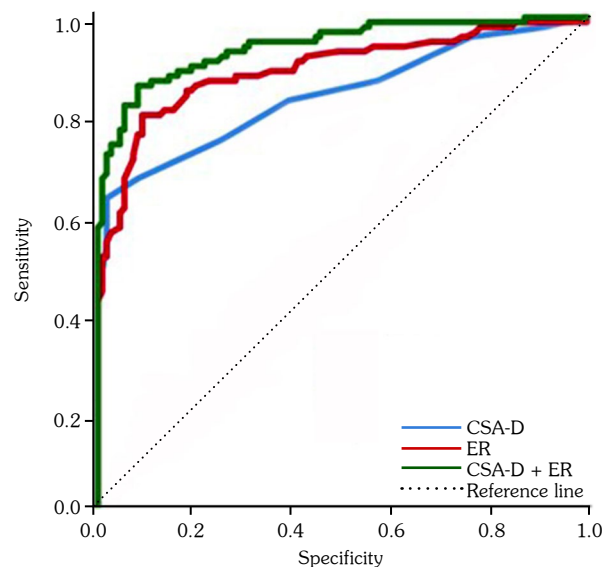
revealed that mean CSA distal to the carpal tunnel (CSA-D), the median WFR, echogenicity, and MN mobility were significantly different ( $p<0.001$ ) between the EDX-positive CTS group and the EDX-normal CTS group, being worse in the positive group. In the EDX-positive CTS group, only 14 wrists had Doppler signals. No changes in the MN vascularity were observed in the EDX-normal CTS group.

Regarding SE assessment, the mean ER at the wrist had highly significant difference ( $p<0.001$ ) between the EDX-normal CTS group and the EDX-positive CTS group, being stiffer in the latter. The median MED/MEP ratio did not show any significant difference between the EDX-normal CTS group and the EDX-positive CTS group (Table 2).

The best cut-off value for ER was 1.195, with a sensitivity of 67%, specificity of 91.8%, and accuracy of 80% (Figure 3).

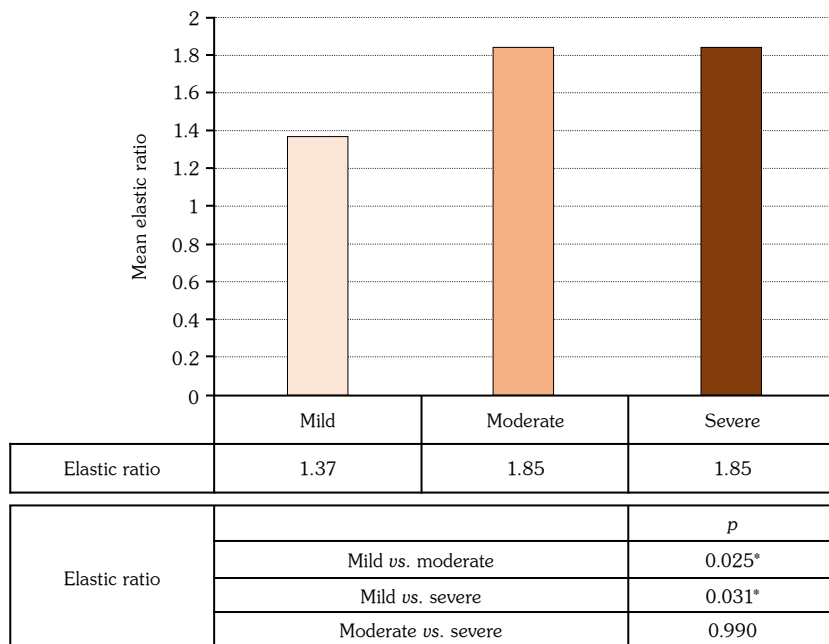
For the evaluation of the difference between the CTS severity stages regarding the NMUS and sonoelastographic findings, a comparison among the subgroups according to EDX results

was done. The results were highly significantly different ( $p<0.001$ ), with CSA-D being the largest in the severe CTS group. The median WFR,



**Figure 3.** ROC curve of ER, CSA-D and combination of both parameters for discrimination between CTS and control groups.

CSA-D: CSA-D: Cross sectional area distal at carpal tunnel; ER: Elastic ratio; ROC: Receiver operating characteristic.



**Figure 4.** ER difference among CTS severity groups.

ER: Elastic ratio; CTS: Carpal tunnel syndrome; S: Significant.

echogenicity, and mobility were significantly different among subgroups ( $p < 0.05$ ).

Although the mean ER was not significant among subgroups (the ER was lowest in the mild EDX group), the median MED/MEP ratio showed a significant difference among the different subgroups of CTS severity ( $p < 0.05$ ). This ratio was lowest in the severe EDX group (Table 3).

When a comparison was done between each stage and the other, it revealed that the mean ER at the wrist had a significant difference between mild CTS compared to moderate or severe CTS ( $p = 0.025$  and  $p = 0.031$ , respectively). However, there was no significant difference in the mean ER between moderate and severe CTS (Figure 4).

A significant difference was observed between the EDX-normal CTS group and the control group in ultrasound and elastographic parameters. The CSA-D of the MN and WFR was significantly larger in the EDX-normal CTS group compared to the healthy controls ( $p < 0.05$ ). Similarly, CSA-D of the MN and WFR were significantly larger in the EDX-positive CTS group compared to the healthy controls ( $p < 0.001$ ). The MN mobility was more limited in the EDX-normal CTS group than in the healthy controls ( $p < 0.001$ ). The limitation of MN

mobility was also higher in the EDX-positive CTS group than in the healthy controls ( $p < 0.05$ ).

The stiffness of the MN was proved to be prominent in CTS patients with normal and positive EDX. This was approved by the more significant decrease in the ER at the wrist in the EDX-normal CTS group and the EDX-positive CTS group compared to the healthy controls ( $p < 0.001$ ). Additionally, the median MED/MEP ratio was higher in the CTS groups than in the control group ( $p < 0.05$ , Table 4).

Focusing on the elasticity of MN in CTS patients with normal EDX who were divided into two groups according to their CSA-D considering a suggested cut-off point of  $12.5 \text{ mm}^2$ , the mean ER was highly significantly different between patients with a CSA-D  $\leq 12.5 \text{ mm}^2$  and patients with CSA-D  $> 12.5 \text{ mm}^2$  ( $p < 0.001$ , being stiffer in the latter, while the MED/MEP ratio difference was nonsignificant) between the two groups ( $p = 0.943$ , Table 5).

Back to the clinical evaluation, a correlation between functional assessment and NMUS parameters in the CTS group was done. There were highly statistically significant positive correlations of the Hi-Ob-Db grade with the



**Table 3.** Comparisons of the NMUS and sonoelastographic findings among subgroups of CTS severity according to EDX results

Parameters	CTS with EDX-positive															p
	Mild (n=20)					Moderate (n=34)					Severe (n=11)					
	n	%	Mean±SD	Median	Range	n	%	Mean±SD	Median	Range	n	%	Mean±SD	Median	Range	
CSA-D			13.6±2.6					17.3±4.6					21.6±6.7			<0.001**
CSA-P			6.3±1.0					6.8±1.3					6.8±1.2			0.348
Wrist/forearm ratio				2.14	1.25-3.80				2.37	1.57-4.50				2.83	1.85-5.66	0.014*
Echogenicity																
N	8	40				3	8.8				0	0.0				0.030*
SR	9	45				22	64.7				7	63.6				
R	3	15				9	26.5				4	36.4				
Mobility																
1	1	5				11	32.4				6	54.5				0.010*
2	11	55				16	47.1				5	45.5				
3	8	40				7	20.6				0	0.0				
Vascularity																
N	20	100				25	73.5				6	54.5				-
SI	0	0				9	26.5				5	45.5				
Flattening ratio			3.0±0.7					3.1±0.7					3.3±0.7			0.591
Elastic ratio			1.4±0.4					1.9±0.5					1.9±0.6			0.062
MED/MEP ratio				1.36	0.6-2.6				1.78	0.6-5.3				1.16	0.5-3.0	0.007*

NMUS: Neuromuscular ultrasound; CTS: Carpal tunnel syndrome; EDX: Electro diagnostic examination; SD: Standard deviation; CSA-D: Cross sectional area distal at carpal tunnel; MED/MEP ratio: MN elasticity between distal and proximal; p: Probability value. \* p<0.05= significant; p>0.05= insignificant; \*\* p<0.001= highly significant.

**Table 4.** Comparisons of the NMUS and sonoelastographic findings among the CTS groups and control group regarding EDX results

Parameters	CTS with EDX-positive																		
	Control group (n=110)					CTS with EDX-normal (n=35)					CTS with EDX-positive (n=65)								
	n	%	Mean±SD	Median	Range	n	%	Mean±SD	Median	Range	n	%	Mean±SD	Median	Range	p <sup>1</sup>	p <sup>2</sup>	p <sup>3</sup>	p <sup>4</sup>
CSA-D			10.4±2.9	1.25	0.75-2.20			16.9±5.5	1.42	0.87-2.50			9±1.9	2.33	1.25-5.66	<0.001**	0.043*	<0.001**	<0.001**
Wrist/forearm ratio																			
Echogenicity																			
Normal	108	98.2				18	51.4				11	16.9							
Slightly	2	1.8				16	45.7				38	58.5							
Reduced	0	0				1	2.9				16	24.6							
Mobility																			
1	0	0				4	11.4				18	27.7							
2	12	10.9				16	45.7				32	49.2							
3	98	89.1				15	42.9				15	23.1							
Vascularity																			
Normal	110	100				35	100				51	78.5							
Slightly increased	0	0				0	0				14	21.5							
Flattening ratio			2.5±0.7					2.6±0.9					3.1±0.7						
Elastic ratio			0.8±0.3					1.5±0.5					1.7±0.6						
MED/MEP ratio				1.26	0.4-4				1.81	0.5-3.2			1.53	0.5-5.3	0.008*	0.006*	0.032*	0.319	

NMUS: Neuromuscular ultrasound; CTS: Carpal tunnel syndrome; EDX: Electro diagnostic examination; SD: Standard deviation; CSA-D: Cross sectional area distal at carpal tunnel; MED/MEP ratio: MN elasticity between distal and proximal; p: Probability value, \* p<0.05= significant; p<0.05= insignificant; \*\* p<0.001= highly significant; p<sup>1</sup>: Comparison between control, EDX-normal, EDX-positive CTS; p<sup>2</sup>: Comparison between control, EDX-normal CTS; p<sup>3</sup>: Comparison between control, EDX-positive CTS; p<sup>4</sup>: Comparison between EDX-normal and EDX-positive CTS.



CSA-D, WFR, and MN vascularity [(r=0.421, p<0.001; r=0.456, p<0.001; r=0.273, p<0.001, respectively)]. There were statistically significant positive correlations of the Hi-Ob-Db grade with the echogenicity and the flattening ratio (r=0.308, p=0.002; r=0.273, p=0.006, respectively). There was a statistically significant negative correlation between the Hi-Ob-Db grade and MN mobility (r=-0.292, p=0.003, Table 6).

Correlations of functional assessment with CTS severity and sonoelastographic findings in the CTS group showed a highly significant positive correlation between the Hi-Ob-Db functional stage and EDX severity of CTS (r=-0.468, p<0.001). There was no significant correlation between the functional assessment and sonoelastographic findings in the CTS group (Table 7).

## DISCUSSION

Although CTS is one of the most common nerve entrapment syndromes, there is no established standard for its diagnosis. It is a clinical diagnosis based on the history, clinical symptoms, and physical examination, including positive provocative clinical tests.<sup>18</sup> EDX is still the main cornerstone in its subjective diagnosis.<sup>19</sup> Currently, ultrasound is successfully used to support the diagnosis of CTS, where sensitivity and specificity have been reported between 57-97.9% and 51-100%, respectively.<sup>15</sup> Sonoelastography has evolved rapidly in recent years with an ever-increasing number of publications. It is a novel ultrasound tool for portraying the strain properties in biological tissues.<sup>20</sup> Since 2013, research has been conducted to study SE in the diagnosis of CTS with promising results.<sup>21</sup>

We here focused on the clinical assessment of the CTS regarding different modalities used in its diagnosis, including EDX, ultrasonographic parameters, and elastography.

Our results showed a statistically significant difference between EDX grades of CTS as regards the symptoms and signs being more obvious in moderate and severe stages. The ultrasonographic parameters were more characteristic for the CTS patients with positive EDX studies than those of negative ones. Regarding the CTS severity based on EDX grading, increasing CSA-D of MN

**Table 5.** Comparisons of ER and MED/MEP ratio among subjects with normal EDX findings and controls regarding CSA-D.

	Control		EDX-normal CTS group				p <sup>1</sup>	p <sup>2</sup>	p <sup>3</sup>	p <sup>4</sup>
	Mean±SD	Median	CSA-D ≤12.5 mm <sup>2</sup>		CSA-D >12.5 mm <sup>2</sup>					
			Mean±SD	Median	Range	Range				
Elastic ratio	0.8±0.2	1.3	1.4±0.4	1.7	0.5-3.2	1.8	0.5-5.3	<0.001**	<0.001**	0.001*
MED/MEP ratio								0.059	0.006*	0.943

ER: Elastic ratio; MED/MEP ratio: MN elasticity between distal and proximal; EDX: Electro diagnostic examination; CTS: Carpal tunnel syndrome; SD: Standard deviation; \* p<0.05= significant; p>0.05= insignificant; \*\* p<0.001= highly significant; p<sup>1</sup>: Comparison among all groups; p<sup>2</sup>: Comparison between control and CSA-D<12.5; p<sup>3</sup>: Comparison between control and CSA-D>12.5; p<sup>4</sup>: Comparison between CSA-D<12.5 and CSA-D>12.5.

**Table 6.** Correlation between functional assessment and NMUS parameters in the CTS group

NMUS parameters	CSA-D	Wrist/forearm ratio	Echogenicity	Mobility	Vascularity	Flattening ratio
Hi-Ob-Db stage						
r	0.421	0.456	0.308	-0.292	0.452	0.273
p	<0.001**	<0.001**	0.002*	0.003*	<0.001**	0.006*

NMUS: Neuromuscular ultrasound; CTS: Carpal tunnel syndrome; CSA-D: Cross sectional area distal at carpal tunnel; Hi-Ob-Db: Historical-objective-distribution-based; p: Probability value; \* p<0.05= significant; p>0.05= insignificant; \*\* p<0.001= highly significant; r: Pearson correlation coefficient.

**Table 7.** Correlations of functional assessment with CTS severity and sonoelastographic findings in the CTS group

Parameters	CTS severity according to EDX	Elastic ratio	MED/MEP
Hi-Ob-Db stage			
r	0.468	0.093	-0.063
p	<0.001*	0.359	0.532

CTS: Carpal tunnel syndrome; EDX: Electrodiagnostic examination; MED/MEP ratio: MN elasticity between distal and proximal; Hi-Ob-Db: Historical-objective-distribution-based; p: Probability value; p<0.05= significant; p>0.05= insignificant; \* p<0.001= Highly significant; r: Pearson correlation coefficient.

was the most prominent feature that showed statistically significant difference, being largest in the severe stage.

The MN elasticity was decreased (stiffer) in the EDX-positive patients at the level of carpal tunnel. Although the ER has no significant difference among the severity groups but still shows significant differences between the mild stage and the moderate and severe ones.

Besides the evidence of the variety of ultrasonographic features as well as the elastographic in the CTS patients than the healthy sample, remarkably, the elasticity was affected in the EDX-normal CTS patients more with CSA-D >12.5 mm<sup>2</sup>. The clinical assessment was correlated with EDX studies and the ultrasound parameters but was not significant enough with the elastography results.

We demonstrated a close link between Tinel's sign and the Hi-Ob-Db clinical scale grading and the EDX severity grades, which matched the results of Sartorio et al.,<sup>22</sup> who concluded the ability of discrimination of the CTS subjects with severe NCS involvement by using the functional dexterity test. Using strain elastography, we found that the MN at the wrist

in CTS patients was highly significantly stiffer than in the healthy controls. In addition, the MED/MEP ratio showed a significant difference between the patient and control groups. The ER correlated significantly with the MN CSA at the carpal tunnel inlet. Furthermore, it correlated with CTS neurophysiological severity grades. These positive correlations demonstrated the increased stiffness of MR with the increased edema and the progression of the disease pathology. We reported that the cut-off value of ER was 1.195, with a sensitivity of 67%, specificity of 91.8%, and accuracy of 80%. Our results agree with the studies that have used strain elastography for the assessment of the MN and found that patients with CTS have a stiffer MN with a larger CSA compared to the healthy population.<sup>7,23</sup> Among previous studies, only the study of Martin and Cartwright<sup>24</sup> reported a nonsignificant difference in the strain ratio between those with CTS and the controls and that the strain ratio did not correlate significantly with the traditional ultrasound parameters of CTS.

Regardless of the ultrasound elastography technique, the MN at the wrist was found to be stiffer than in healthy controls. The hardness

detected by the elastography reflects the histological quantitative changes in the MN. The pathophysiology of CTS is believed to be a combination of increased intracarpal tunnel pressure and ischemic injury in the MN. Increased pressure in the carpal tunnel causes stagnation or blockage of venous outflow and provokes venous congestion and hyperemia, followed by intraneural edema. Long-term edema causes fibroblast invasion, which results in perineural thickening, nerve fiber changes and the accumulation of scar tissue inside the MN, which led to an increased stiffness of the nerve.<sup>25</sup> Fibrosis of the MN in CTS is not only caused by intraneural edema but also changes in the oxidative stress and the antioxidant defenses could be relevant to fibrosis through the disturbed signaling pattern in the tenosynovium.<sup>26</sup>

#### **Role of SE in the prognosis of CTS and differentiation of disease severity**

EDX has been used to determine the severity of CTS. However, the procedure is uncomfortable for patients and has a false-negative rate between 16 and 34%.<sup>27,28</sup> Sonoelastography may provide an alternative tool for the diagnosis as well as determining the severity of CTS. This tool is easy, rapid, and well-tolerated by patients.

In our study, the ER at the wrist showed a significant difference when compared between mild, moderate, and severe CTS. However, there was no significant difference between moderate CTS and severe CTS. Our results were consistent with research that found the strain ratio was able to categorize the cases into mild, moderate, and severe CTS with some overlap between the groups.<sup>7,19,29</sup> No differences were reported in MN stiffness between mild CTS and moderate to severe CTS.<sup>15,30</sup>

Although we were unable to precisely distinguish between all grades of the severity of CTS based on the strain ratio, there is still value in being able to identify patients in the moderate and severe categories. This may help in the choice of therapy that may provide the best benefit to the patient, either conservative treatment or surgical intervention. We suggest that strain elastography may have a prognostic value in CTS. It may provide additive information for follow-up and evaluating the efficacy of therapy.

Two studies have evaluated the effect of local corticosteroid injection in CTS by comparing strain ratio pre- and posttreatment. Miyamoto et al.<sup>31</sup> found significant improvement in MN stiffness at the end of the therapy compared to the baseline measurements. In contrast, Asadov et al.<sup>32</sup> reported a nonsignificant change in the MN elasticity after treatment. Tezcan et al.<sup>33</sup> evaluated the efficacy of low-level laser therapy on MN stiffness in CTS using strain elastography and found that the strain ratio in the posttreatment CTS improved. Yoshii et al.<sup>34</sup> compared MN elasticity before and after surgical carpal tunnel release and stated that the elasticity of the MN recovers quickly after the release.

#### **The value of elastography in patients with CTS and negative electrodiagnostic studies**

In our study, 35% of patients with clinically diagnosed CTS had negative EDX results. In a review of the EDX for the American Association of Electrodiagnostic Medicine, Jablecki et al.<sup>35</sup> found that EDX missed the diagnosis of CTS in 16 to 34% of patients with a clinically defined disease. It was proven that several patients with CTS could have swelling of the MN detectable by the ultrasound with no impairment in the EDX.<sup>36</sup> Symptoms such as paresthesia can appear before nerve conduction impairment can be detected by EDX, which assesses only the larger fibers. Furthermore, in mild compression or posture-dependent compression, there is no myelin deficiency, and the EDX results may remain negative.<sup>37,38</sup> Taking this point into consideration, we investigated the value of the MN ER in CTS patients with negative EDX results in addition to normal CSA-D (less than our proposed cut-off value of 12.5 mm<sup>2</sup>). In the EDX-normal group, we found that the MN nerve was stiffer in both subgroups (patients with CSA-D  $\leq$ 12.5 mm<sup>2</sup> and patients with CSA-D  $>$ 12.5 mm<sup>2</sup>) compared to the controls. This highlighted that the elasticity of MN could be affected before the enlargement of its CSA (beginning of the edema). Thus, elastography may allow early diagnosis of CTS. Moran et al.<sup>39</sup> reported comparable results using shear wave elastography and found that the MN CSA was not larger in patients with negative EDX findings than in the healthy participants while showing higher MN stiffness compared to the same volunteers.

The limitation of the study was the dependence on the ER in the elastography evaluation with the relative structure, which was the tendon of the flexor carpi radialis outside the carpal tunnel. This was the nearest structure in the same electrogram, and it being outside the carpal tunnel decreased the probability of getting affected by the same disorder that caused MN issues. A recommendation is to target the symptomatic CTS patients with negative EXD studies to highlight the role of the ultrasound in combination with elastography for early detection and proper treatment.

In conclusion, SE has a potential diagnostic value in CTS especially in patients with positive clinical presentation and normal electrodiagnosis. Moreover it can distinguish its severity.

**Ethics Committee Approval:** The study protocol was approved by the Benha University Faculty of Medicine Ethics Committee (date: September 2019, no: MD.5.5 2019). The study was conducted in accordance with the principles of the Declaration of Helsinki.

**Patient Consent for Publication:** A written informed consent was obtained from each patient.

**Data Sharing Statement:** The data that support the findings of this study are available from the corresponding author upon reasonable request.

**Author Contributions:** Creative thinking, writing, practical part, and corresponding author: M.Y.; Supervision and practical guidance: A.E.S.; Supervision and practical guidance: D.L.

**Conflict of Interest:** The authors declared no conflicts of interest with respect to the authorship and/or publication of this article.

**Funding:** The authors received no financial support for the research and/or authorship of this article.

## REFERENCES

- Atroshi I, Gummesson C, Johnsson R, Ornstein E, Ranstam J, Rosén I. Prevalence of carpal tunnel syndrome in a general population. *JAMA* 1999;282:153-8. doi: 10.1001/jama.282.2.153.
- de Krom MC, Knipschild PG, Kester AD, Thijs CT, Boekkooi PF, Spaans F. Carpal tunnel syndrome: Prevalence in the general population. *J Clin Epidemiol* 1992;45:373-6. doi: 10.1016/0895-4356(92)90038-o.
- Nam K, Peterson SM, Wessner CE, Machado P, Forsberg F. Diagnosis of carpal tunnel syndrome using shear wave elastography and high-frequency ultrasound imaging. *Acad Radiol* 2021;28:e278-87. doi: 10.1016/j.acra.2020.08.011.
- Snoj Ž, Wu CH, Taljanovic MS, Dumić-Čule I, Drakonaki EE, Klauser AS. Ultrasound elastography in musculoskeletal radiology: Past, present, and future. *Semin Musculoskelet Radiol* 2020;24:156-66. doi: 10.1055/s-0039-3402746.
- Miyamoto H, Morizaki Y, Kashiyama T, Tanaka S. Grey-scale sonography and sonoelastography for diagnosing carpal tunnel syndrome. *World J Radiol* 2016;8:281-7. doi: 10.4329/wjr.v8.i3.281.
- Taljanovic MS, Gimber LH, Becker GW, Latt LD, Klauser AS, Melville DM, et al. Shear-wave elastography: Basic physics and musculoskeletal applications. *Radiographics* 2017;37:855-70. doi: 10.1148/rg.2017160116.
- Elsayed M, Saber Mohamed MA, Afifi LM, Wafaie AM. The role of sonoelastography in diagnosis and grading of patients with carpal tunnel syndrome. *Med J Cairo Univ* 2021;89:2203-11. doi: 10.21608/mjcu.2021.203691.
- Ogur T, Yakut ZI, Teber MA, Alp F, Turan A, Tural A, et al. Ultrasound elastographic evaluation of the median nerve in pregnant women with carpal tunnel syndrome. *Eur Rev Med Pharmacol Sci* 2015;19:23-30.
- Nam K, Peterson SM, Wessner CE, Machado P, Forsberg F. Diagnostic performance of shear wave elastography for carpal tunnel syndrome combined with high frequency ultrasound imaging. 2020 IEEE International Ultrasonics Symposium (IUS), Las Vegas, NV, USA, 2020. p. 1-4, doi: 10.1109/IUS46767.2020.9251485.
- Mohammadi A, Afshar A, Mirza-Aghazadeh-Attari M, Mokhtari SAS. Application of shear wave elastography and median nerve cross-section area in the diagnosis and staging of carpal tunnel syndrome: A case-control study. *Pol J Radiol* 2021;86:e638-43. doi: 10.5114/pjr.2021.111437.
- Lasheen DR, Abdelmoneam SM, El Shambaky AY, Mahgoub MY. Sonoelastography of the median nerve in carpal tunnel syndrome in correlation with nerve conduction studies. *BJAS* 2021;6:357-63.
- Caliandro P, Giannini F, Pazzaglia C, Aprile I, Minciotti I, Granata G, et al. A new clinical scale to grade the impairment of median nerve in carpal tunnel syndrome. *Clin Neurophysiol* 2010;121:1066-71. doi: 10.1016/j.clinph.2010.02.002.
- American Association of Electrodiagnostic Medicine, American Academy of Neurology, and American Academy of Physical Medicine and Rehabilitation. Practice parameter for electrodiagnostic studies in carpal tunnel syndrome: Summary statement. *Muscle Nerve* 2002;25:918-22. doi: 10.1002/mus.10185.
- Bland JD. A neurophysiological grading scale for carpal tunnel syndrome. *Muscle Nerve* 2000;23:1280-3. doi: 10.1002/1097-4598(200008)23:8<1280::aid-mus20>3.0.co;2-y.

15. Tatar IG, Kurt A, Yavasoglu NG, Hekimoglu B. Carpal tunnel syndrome: Elastosonographic strain ratio and cross-sectional area evaluation for the diagnosis and disease severity. *Med Ultrason* 2016;18:305-11. doi: 10.11152/mu.2013.2066.183.tat.
16. Faul F, Erdfelder E, Lang AG, Buchner A. G\*Power 3: A flexible statistical power analysis program for the social, behavioral, and biomedical sciences. *Behav Res Methods* 2007;39:175-91. doi: 10.3758/bf03193146.
17. Ibrahim HR. Diagnostic value of median nerve shear wave ultrasound elastography in diagnosis and differentiation of carpal tunnel syndrome severity. *Egypt J Radiol Nucl Med* 2021;52:187. doi: 10.1186/s43055-021-00573-3.
18. Genova A, Dix O, Saefan A, Thakur M, Hassan A. Carpal tunnel syndrome: A review of literature. *Cureus* 2020;12:e7333. doi: 10.7759/cureus.7333.
19. Ciloglu O, Görgülü FF. Which ultrasound parameter is more accurate in the diagnosis of carpal tunnel syndrome: Cross-sectional area, resistive index, or strain ratio? *Am J Phys Med Rehabil* 2020;99:842-6. doi: 10.1097/PHM.0000000000001464.
20. Lin CP, Chen IJ, Chang KV, Wu WT, Özçakar L. Utility of ultrasound elastography in evaluation of carpal tunnel syndrome: A systematic review and meta-analysis. *Ultrasound Med Biol* 2019;45:2855-65. doi: 10.1016/j.ultrasmedbio.2019.07.409.
21. van Holsbeeck M, Soliman S, Van Kerkhove F, Craig J. Advanced musculoskeletal ultrasound techniques: What are the applications? *AJR Am J Roentgenol* 2021;216:436-45. doi: 10.2214/AJR.20.22840.
22. Sartorio F, Dal Negro F, Bravini E, Ferriero G, Corna S, Invernizzi M, et al. Relationship between nerve conduction studies and the Functional Dexterity Test in workers with carpal tunnel syndrome. *BMC Musculoskelet Disord* 2020;21:679. doi: 10.1186/s12891-020-03651-1.
23. Karatay E, Türkoğlu Ö, Mansız Kaplan B. Assessment of diagnostic efficiency of real-time strain elastography by using the median nerve stiffness at females with carpal tunnel syndrome. *Cukurova Med J* 2020;45:1276-82. doi: 10.17826/cumj.745698.
24. Martin MJ, Cartwright MS. A pilot study of strain elastography in the diagnosis of carpal tunnel syndrome. *J Clin Neurophysiol* 2017;34:114-8. doi: 10.1097/WNP.0000000000000334.
25. Cingoz M, Kandemirli SG, Alis DC, Samanci C, Kandemirli GC, Adatepe NU. Evaluation of median nerve by shear wave elastography and diffusion tensor imaging in carpal tunnel syndrome. *Eur J Radiol* 2018;101:59-64. doi: 10.1016/j.ejrad.2018.02.005.
26. Orman G, Ozben S, Huseyinoglu N, Duyumus M, Orman KG. Ultrasound elastographic evaluation in the diagnosis of carpal tunnel syndrome: Initial findings. *Ultrasound Med Biol* 2013;39:1184-9. doi: 10.1016/j.ultrasmedbio.2013.02.016.
27. Atroschi I, Gummesson C, Johnsson R, Ornstein E. Diagnostic properties of nerve conduction tests in population-based carpal tunnel syndrome. *BMC Musculoskelet Disord* 2003;4:9. doi: 10.1186/1471-2474-4-9.
28. Witt JC, Hentz JG, Stevens JC. Carpal tunnel syndrome with normal nerve conduction studies. *Muscle Nerve* 2004;29:515-22. doi: 10.1002/mus.20019.
29. Emara DM, El Shafei MM, Abdel Naby HM. Utility of ultrasound elastography in a cohort of patients with idiopathic carpal tunnel syndrome. *EJRNM* 2018;49:408-14.
30. Park EJ, Hahn S, Yi J, Shin KJ, Lee Y, Lee HJ. Comparison of the diagnostic performance of strain elastography and shear wave elastography for the diagnosis of carpal tunnel syndrome. *J Ultrasound Med* 2021;40:1011-21. doi: 10.1002/jum.15478.
31. Miyamoto H, Halpern EJ, Kastlunger M, Gabl M, Arora R, Bellmann-Weiler R, et al. Carpal tunnel syndrome: Diagnosis by means of median nerve elasticity--improved diagnostic accuracy of US with sonoelastography. *Radiology* 2014;270:481-6. doi: 10.1148/radiol.13122901.
32. Asadov R, Erdal A, Buğdaycı O, Gündüz OH, Ekinci G. The effectiveness of ultrasonography and ultrasonographic elastography in the diagnosis of carpal tunnel syndrome and evaluation of treatment response after steroid injection. *Eur J Radiol* 2018;108:172-6. doi: 10.1016/j.ejrad.2018.09.027.
33. Tezcan S, Ulu Ozturk F, Uslu N, Nalbant M, Umit Yemisci O. Carpal tunnel syndrome: Evaluation of the effects of low-level laser therapy with ultrasound strain imaging. *J Ultrasound Med* 2019;38:113-22. doi: 10.1002/jum.14669.
34. Yoshii Y, Tung WL, Yuine H, Ishii T. Postoperative diagnostic potentials of median nerve strain and applied pressure measurement after carpal tunnel release. *BMC Musculoskelet Disord* 2020;21:22. doi: 10.1186/s12891-019-3033-y.
35. Jablecki CK, Andary MT, So YT, Wilkins DE, Williams FH. Literature review of the usefulness of nerve conduction studies and electromyography for the evaluation of patients with carpal tunnel syndrome. *AAEM Quality Assurance Committee. Muscle Nerve* 1993;16:1392-414. doi: 10.1002/mus.880161220.
36. Aseem F, Williams JW, Walker FO, Cartwright MS. Neuromuscular ultrasound in patients with carpal tunnel syndrome and normal nerve conduction studies. *Muscle Nerve* 2017;55:913-5. doi: 10.1002/mus.25462.
37. Moran L, Perez M, Esteban A, Bellon J, Arranz B, del Cerro M. Sonographic measurement of cross-sectional area of the median nerve in the diagnosis of carpal tunnel syndrome: Correlation with nerve conduction studies. *J Clin Ultrasound* 2009;37:125-31. doi: 10.1002/jcu.20551.

38. Ratasvuori M, Sormaala M, Kinnunen A, Lindfors N. Ultrasonography for the diagnosis of carpal tunnel syndrome: Correlation of clinical symptoms, cross-sectional areas and electroneuromyography. *J Hand Surg Eur Vol* 2022;47:369-74. doi: 10.1177/17531934211059808.
39. Moran L, Royuela A, de Vargas AP, Lopez A, Cepeda Y, Martinelli G. Carpal tunnel syndrome: Diagnostic usefulness of ultrasound measurement of the median nerve area and quantitative elastographic measurement of the median nerve stiffness. *J Ultrasound Med* 2020;39:331-9. doi: 10.1002/jum.15111.