

Mepolizumab therapy in a pediatric patient with eosinophilic granulomatosis with polyangiitis associated with refractory myocarditis

Kadir Ulu¹, Şengül Çağlayan¹, Ayşen Çetemen², Mustafa Çakan¹, Taliha Öner³, Betül Sözeri¹

¹Department of Pediatric Rheumatology, Ümraniye Training and Research Hospital, Istanbul, Türkiye

²Department of Pediatric Allergy and Immunology, Ümraniye Training and Research Hospital, Istanbul, Türkiye

³Department of Pediatric Cardiology, Ümraniye Training and Research Hospital, Istanbul, Türkiye

Eosinophilic granulomatosis with polyangiitis (EGPA) belongs to the family of antineutrophil cytoplasmic antibody (ANCA)-associated vasculitides. It is an eosinophil-rich, necrotizing granulomatous vasculitis affecting small to medium vessels. Interleukin (IL)-5 is the most potent stimulator of eosinophil production and functional activation of mature eosinophils, the key effector cells in EGPA. Mepolizumab is a humanized monoclonal antibody that inhibits IL-5.¹

A 17-year-old female patient was admitted with complaints of a rash on the feet, a lesion on the palate, and cough. Her medical records showed that she used inhaler and systemic corticosteroid treatment with the diagnosis of asthma and allergic pulmonary aspergillosis for two years. Physical examination revealed a 1 cm² ulcerated lesion on the upper palate, petechial rash on bilateral feet, and expiratory rhonchus in lung auscultation. Complete blood count showed eosinophilia (white blood cell count: $10.7 \times 10^3/\mu\text{L}$, eosinophil count: $1.5 \times 10^3/\mu\text{L}$). Acute phase reactants and

troponin I levels were elevated [C-reactive protein: 17 mg/L (normal <5 mg/L), erythrocyte sedimentation rate: 44 mm/h (normal <20 mm/h), troponin I level: 15.7 ng/mL (normal <0.026 ng/mL)]. PR3 (proteinase 3)-ANCA and MPO (myeloperoxidase)-ANCA were negative. At presentation, pansinusitis was determined in the paranasal magnetic resonance imaging, and computed tomography revealed ground-glass opacities and interlobular septal thickenings in bilateral lung parenchyma (crazy-paving pattern), peribronchial thickenings, and occasional discoid atelectasis (Figure 1). Bone marrow evaluation revealed an increase in the eosinophilic series, and leukemia was ruled out. Eosinophilic infiltration was detected in the biopsy sample taken from the lesion on the palate. The patient was diagnosed with EGPA based on the American College of Rheumatology classification criteria. High-dose methylprednisolone pulse and intravenous immunoglobulin therapy were administered to the patient, and methotrexate was added to the treatment regimen. Good symptom control was

Received: August 02, 2022 **Accepted:** October 21, 2022 **Published online:** December 01, 2022

Correspondence: Kadir Ulu, MD. Ümraniye Eğitim ve Araştırma Hastanesi, Çocuk Romatoloji Kliniği, 34764 Ümraniye, Istanbul, Türkiye.
E-mail: drkadirulu@gmail.com

Citation:

Ulu K, Çağlayan Ş, Çetemen A, Çakan M, Öner T, Sözeri B. Mepolizumab therapy in a pediatric patient with eosinophilic granulomatosis with polyangiitis associated with refractory myocarditis. Arch Rheumatol 2023;38(x):i-iii.

©2023 Turkish League Against Rheumatism. All rights reserved.

This is an open access article under the terms of the Creative Commons Attribution-NonCommercial License, which permits use, distribution and reproduction in any medium, provided the original work is properly cited and is not used for commercial purposes (<http://creativecommons.org/licenses/by-nc/4.0/>).

achieved on the second week of this treatment. Two months after discharge, she was readmitted with the complaint of syncope and chest pain. A 14 mm pericardial effusion was detected by echocardiography. Cardiac magnetic resonance imaging and laboratory data were consistent with acute myocarditis. Cyclophosphamide therapy was initiated at a dose of 500 mg per month. After the third dose of cyclophosphamide, myocarditis and pericardial effusion relapsed, and rituximab treatment was commenced. The child had a good initial response to rituximab, but pericardial effusion recurred in the third month of the therapy, and at that time, the highest percentage of eosinophils in complete blood count (60.6%) was observed. Rituximab was switched to mepolizumab (100 mg/month). After the second dose of mepolizumab treatment, eosinophil counts returned to the normal range, and pericardial effusion completely regressed. The dose of methylprednisolone was tapered and then stopped on the second month of mepolizumab treatment. Eosinophil percentage and troponin I levels before and after mepolizumab treatment are shown in Figure 2. No mepolizumab-related adverse event was observed. She has been followed for one year in complete remission under mepolizumab treatment.

Eosinophilic granulomatosis with polyangiitis is a rare vasculitis that can cause life-threatening symptoms and may present with diverse clinics. In a cohort of nine pediatric EGPA patients,

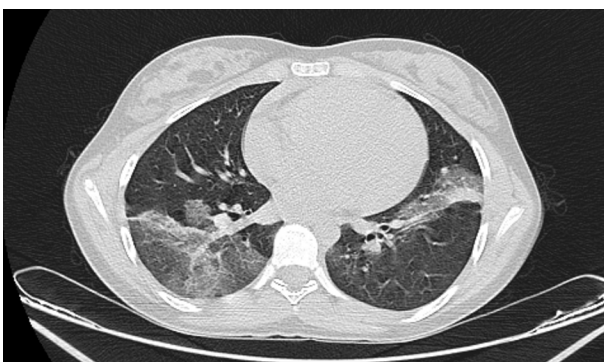


Figure 1. The view of computed tomography on admission. It reveals ground-glass opacities and interlobular septal thickenings in the bilateral lung parenchyma (crazy-paving pattern), peribronchial thickenings, and occasional discoid atelectasis.

all patients had eosinophilia, upper respiratory disease, and lung involvement. Skin findings were detected in 67% of the patients, and cardiac symptoms were present in 44%. Compared to adult EGPA cases, lung involvement and heart disease were found to be significantly higher in pediatric patients. In addition, omalizumab was used in one patient.² Sahin et al.³ reported a 14-year-old boy who was previously misdiagnosed as having cutaneous anthrax that presented with multiple large and deep ulceronecrotic lesions on the lower extremities. It was emphasized that EGPA should be considered in the differential diagnosis of patients with vasculitic lesions, eosinophilia, and a history of asthma.

An adult study comparing mepolizumab and placebo in EGPA patients showed an approximately 50% reduction in relapse rate over one year in the mepolizumab group. Twenty-eight percent of the patients in the mepolizumab group had complete remission for at least 24 weeks compared to 3% in the placebo group.⁴ In another study, in which 18 patients with EGPA were included, the benefits of low-dose mepolizumab (100 mg/month) were shown in asthma from the perspective of disease exacerbations and steroid-sparing effects.⁵ To our knowledge, there are three pediatric EGPA cases successfully treated with mepolizumab in the literature.⁶⁻⁸ In this case with relapsing and refractory myocarditis, the clinical efficacy of mepolizumab is presented without any adverse events for one year. Mepolizumab seems to be a safe treatment option in eosinophil-related end-organ inflammation for pediatric cases.

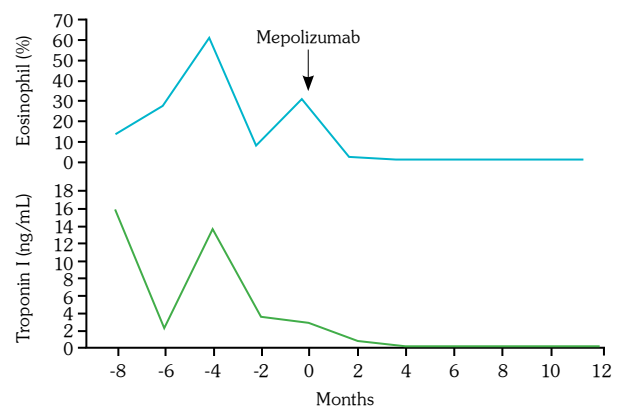


Figure 2. Eosinophil percentages and troponin I values before and after mepolizumab treatment.

Patient Consent for Publication: A written informed consent was obtained from patient.

Data Sharing Statement: The data that support the findings of this study are available from the corresponding author upon reasonable request.

Author Contributions: Concept: B.S.; Design: B.S., K.U., Literature review: K.U., M.Ç.; Control/supervision: B.S., M.Ç.; Data collection: K.U., Ş.Ç., A.Ç., T.Ö.; Writing the article: B.S., K.U. All authors made substantial contributions to the interpretation of data for the work. All authors were involved in drafting the article or revising it critically, and all authors approved the final version of the manuscript.

Conflict of Interest: The authors declared no conflicts of interest with respect to the authorship and/or publication of this article.

Funding: The authors received no financial support for the research and/or authorship of this article.

REFERENCES

1. Uzzo M, Regola F, Trezzi B, Toniati P, Franceschini F, Sinico RA. Novel targets for drug use in eosinophilic granulomatosis with polyangiitis. *Front Med (Lausanne)* 2021;8:754434. doi: 10.3389/fmed.2021.754434.
2. Gendelman S, Zeft A, Spalding SJ. Childhood-onset eosinophilic granulomatosis with polyangiitis (formerly Churg-Strauss syndrome): A contemporary single-center cohort. *J Rheumatol* 2013;40:929-35. doi: 10.3899/jrheum.120808.
3. Sahin S, Adrovic A, Barut K, Kasapcopur O. Childhood-onset eosinophilic granulomatosis with polyangiitis: A rare childhood vasculitis mimicking anthrax and eosinophilic leukaemia. *BMJ Case Rep* 2016;2016:bcr2015213856. doi: 10.1136/bcr-2015-213856.
4. Wechsler ME, Akuthota P, Jayne D, Khoury P, Klion A, Langford CA, et al. Mepolizumab or placebo for eosinophilic granulomatosis with polyangiitis. *N Engl J Med* 2017;376:1921-32. doi: 10.1056/NEJMoa1702079.
5. Vultaggio A, Nencini F, Bormioli S, Vivarelli E, Dies L, Rossi O, et al. Low-dose mepolizumab effectiveness in patients suffering from eosinophilic granulomatosis with polyangiitis. *Allergy Asthma Immunol Res* 2020;12:885-93. doi: 10.4168/aaair.2020.12.5.885.
6. Awouters M, De Somer L, Wouters C, Proesmans M, Boon M. Mepolizumab in childhood onset steroid dependent eosinophilic granulomatosis with polyangiitis. *Pediatr Pulmonol* 2021;56:16-8. doi: 10.1002/ppul.25122.
7. Joseph MX, Jenkins LE, Wechsler ME, Davis LS. Mepolizumab treatment of pediatric eosinophilic granulomatosis with polyangiitis. *JAMA Dermatol* 2018;154:486-7. doi: 10.1001/jamadermatol.2017.5888.
8. Nara M, Saito M, Abe F, Komatsuda A, Wakui H, Takahashi N. A Pediatric case of relapsing eosinophilic granulomatosis with polyangiitis successfully treated with mepolizumab. *Intern Med* 2019;58:3583-7. doi: 10.2169/internalmedicine.3406-19.