

## CASE REPORT

## Leptospirosis With Acute Renal Failure and Vasculitis: A Case Report

Sibel YÜCEL KOÇAK<sup>id</sup>, Ayşegül KUDU<sup>id</sup>, Arzu KAYALAR<sup>id</sup>, Mürvet YILMAZ<sup>id</sup>, Süheyla APAYDIN<sup>id</sup>*Department of Nephrology, University of Health Sciences, Bakırköy Dr. Sadi Konuk Training and Research Hospital, İstanbul, Turkey***ABSTRACT**

Leptospirosis is a zoonotic disease that occurs worldwide. Various clinical manifestations of leptospirosis can be seen. In this article, we present a case with acute renal failure, severe vasculitis and hyperbilirubinemia occurring simultaneously with leptospirosis. A 45-year-old male patient presented with fever, myalgia, jaundice and reddish skin lesions and anuria. Physical examination findings were icteric sclera, large tender hepatomegaly, and lower extremities' cutaneous necrosis due to vasculitis. Hemodialysis was started. Kidney biopsy revealed degenerative changes of proximal tubules, some of them containing bile casts. Microscopic agglutination test was positive and consistent with leptospirosis. Intravenous ampicillin and oral tetracycline were started. Methylprednisolone 60 mg per day was given for skin vasculitis. Hemodialysis therapy was discontinued. All clinical findings gradually regressed.

**Keywords:** Leptospirosis, renal failure, vasculitis, Weil's disease.

Leptospirosis is one of the most common and important zoonotic infections worldwide. Leptospirosis generally presents with features of bacterial infection in acute phase followed by multi-organ complications and may be complicated by jaundice and renal failure, pulmonary hemorrhage, acute respiratory distress syndrome, myocarditis, rhabdomyolysis, Sweet's and uveitis.<sup>1</sup> Acute pancreatitis and myocarditis are very rare manifestations in leptospirosis.<sup>2,3</sup> In addition, vasculitis and gangrene are also uncommon complications. In this article, we present a rare case of acute renal failure and hyperbilirubinemia occurring simultaneously, severe vasculitis with peripheral gangrene of the lower extremities with leptospirosis.

## CASE REPORT

A 45-year-old male patient was admitted to our clinic with a seven-day history of fever, myalgia, jaundice and reddish skin lesions. He also had anuria over the previous two days. On examination, the patient was mildly tachycardic (120/minute) with a blood pressure of 180/90 mmHg, pyrexia (38.4°C) and tachypnea (24/minute). Physical examination findings were icteric sclera, remarkable for jaundice and large tender hepatomegaly, cutaneous necrosis of the feet due to vasculitis (Figure 1). Abdominal organomegaly could not be assessed because the patient had severe rigidity and tenderness to palpation and percussion. There was no rebound

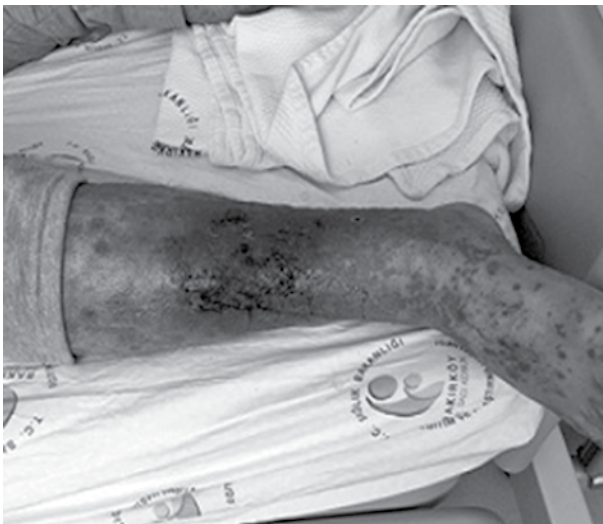**Received:** June 05, 2018 **Accepted:** September 28, 2018 **Published online:** November 30, 2018

**Correspondence:** Sibel Yücel Koçak, MD. SBÜ Bakırköy Dr. Sadi Konuk Eğitim ve Araştırma Hastanesi, Nefroloji Kliniği, 34147 Bakırköy, İstanbul, Turkey.  
Tel: +90 505 - 583 08 60 e-mail: fsibelkocak@yahoo.com

*This study was presented at the 54<sup>th</sup> European Renal Association-European Dialysis and Transplant Association Congress, June 3-6, 2017, Madrid, Spain.*

**Citation:**

Yücel Koçak S, Kudu A, Kayalar A, Yılmaz M, Apaydin S. Leptospirosis With Acute Renal Failure and Vasculitis: A Case Report. Arch Rheumatol 2019;34(2):229-232.



**Figure 1.** Necrosis of soft tissue in lower extremity due to vasculitis.

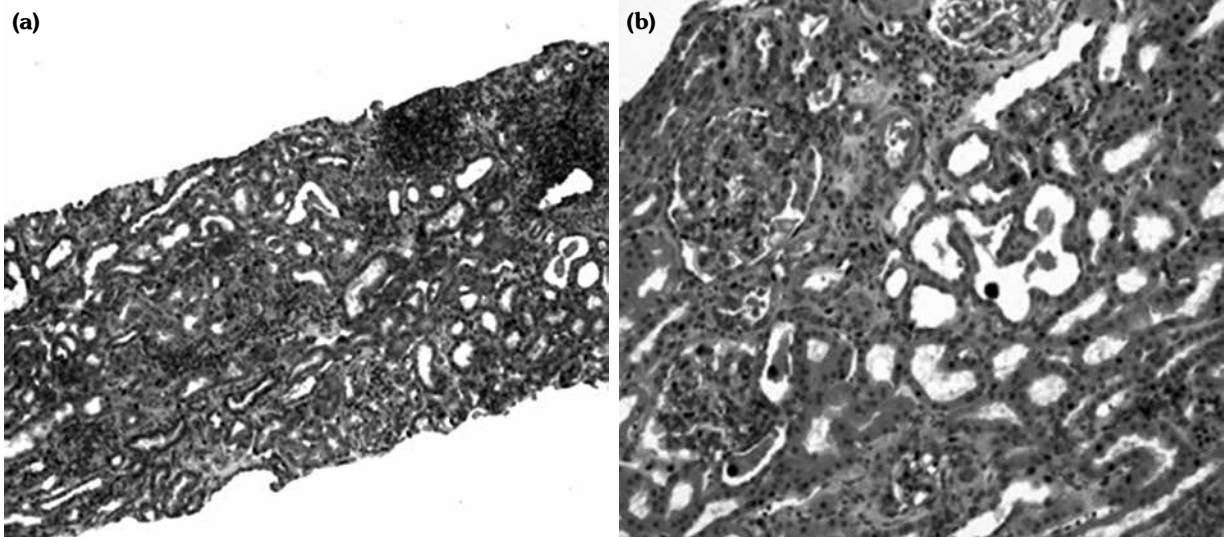
tenderness. Laboratory studies demonstrated hyperkalemia (6.0 mEq/L), metabolic acidosis, respiratory alkalosis and anion gap acidosis, as well as acute kidney injury (blood urea

nitrogen 233 mg/dL, creatinine 18.6 mg/dL, uric acid 20 mg/dL, pH 7.31, bicarbonate 15.7 mmol/L, anion gap 21 mEq/L). Aspartate aminotransferase and alanine aminotransferase were not elevated (28 mEq/L and 51 mEq/L, respectively) and there was significant hyperbilirubinemia (total bilirubin 13.4 mEq/L, direct bilirubin 11.4 mEq/L). Coagulation studies were normal (Table 1). Hepatitis B surface antigens, hepatitis C antibodies and anti-human immunodeficiency virus antibody titers were all negative. A written informed consent was obtained from the patient.

Urinalysis revealed hematuria, mild proteinuria (380 mg/day), bilirubin and granular casts. Abdominal ultrasound showed severe hepatomegaly with steatotic transformation without intra-hepatic cholestasis and kidneys with normal size and parenchymal echogenicity. Only hepatosplenomegaly was seen in magnetic resonance cholangiopancreatography. Hemodialysis was started for acute renal failure. Kidney and skin biopsies were performed. Histopathology of the skin lesions was

**Table 1.** Laboratory parameters of reported case with leptospirosis

Test	First parameters	First parameters	Reference value
Hemoglobin (g/dL)	14.1	15.8	12.9-15.9
Leucocytes (cells × 10 <sup>9</sup> /L)	8.3	6.5	3.7-10.1
Platelets (cells × 10 <sup>9</sup> /L)	342	265	155-366
Urea (mg/dL)	466	32	16-48
Creatinine (mg/dL)	18.6	0.7	0.7-1.2
K <sup>+</sup> (mmol/L)	6	4.9	3.3-5.1
Na <sup>+</sup> (mmol/L)	133	136	136-145
Uric acid (mg/dL)	20	6.1	2.4-6
Total bilirubin (mg/dL)	13.4	1.35	1.1
Direct bilirubin (mg/dL)	11.4	1	1.2
Aspartate aminotransferase (IU/L)	28	27	0-32
Alanine aminotransferase (IU/L)	51	31	0-32
Gamma-glutamyl transferase (IU/L)	127	30	5-36
Serum amylase (IU/L)	132	94	100
Lactate dehydrogenase (IU/L)	327	200	135-214
Total protein (g/dL)	7.1	8.5	6.4-8.3
Albumins (g/dL)	3.3	5	3.5-5.2
Prothrombin time (sn)	1.27	1	0.8-1.2
Creatinekinase (IU/L)	53	100	0-170
C-reactive protein (mg/dL)	6.4	0.5	0.5



**Figure 2.** (a) Interstitial inflammation mainly composed of mononuclear inflammatory cells (H-E×10). (b) Proximal tubules showing degenerative changes, some of them containing bile casts (H-E×20).

lymphocytic vasculitis in favor of pigmented purpuric dermatosis. Renal biopsy revealed normal 26 glomeruli, diffuse mononuclear cell infiltration in tubulointerstitial area (Figure 2a) and proximal tubules showing degenerative changes, some of them containing bile casts (Figure 2b). Immunofluorescence stains were negative. All cultures, Brucella agglutination, blood smear and autoimmune antibodies were negative. Only microscopic agglutination test (MAT=1/50) was positive and consistent with leptospirosis. Intravenous ampicillin and oral tetracycline were started. Methylprednisolone 60 mg per day was given for skin vasculitis. All clinical findings gradually regressed. Hemodialysis was discontinued after four sessions.

## DISCUSSION

Icteric leptospirosis is a severe disease with a rapidly progressive clinical course. Severe cases often present late in the course of the disease contributing to the high mortality rate, which ranges between 5% and 15%. The complications of severe leptospirosis emphasize the multisystemic nature of the disease. Leptospirosis presenting with renal failure and jaundice is known as Weil's disease. Jaundice with high bilirubin levels is present in almost all cases of severe leptospirosis and contributes to severe acute kidney injury.<sup>2</sup> In

a report from Israel, the disease was associated with jaundice in 71% of cases, acute renal failure in 62%, rhabdomyolysis in 52%, pancytopenia in 28%, respiratory failure in 14% and disseminated intravascular coagulation in 5%.<sup>4</sup> Leptospirosis may occur in two phases. In the first phase, the symptoms which can be observed are fever, chills, severe headache, nausea, vomiting, myalgia and diarrhea. The second phase is called Weil's disease which is more severe and the symptoms include sepsis with multiple organ dysfunction, jaundice and hemorrhage which may turn to circulatory shock and eventually death.<sup>5</sup> Pulmonary injury often presents with hemorrhage that has been related to toll-like receptor (TLR) activation from *Leptospira* lipoproteins.<sup>6</sup> Acute renal failure, also associated with TLR activation, is reported in 16-40% of cases where oliguria is a significant predictor of death.<sup>7</sup> *Leptospira* lipoprotein triggers inflammatory responses in renal proximal tubule cells by activation of TLR2, nuclear factor ( $\kappa$ ) B and mitogen-activated protein kinases. One study reported myocarditis, pancreatitis, polyarthritis, mononeuritis multiplex and vasculitis with symmetrical peripheral gangrene of the lower extremities.<sup>7</sup> Vasculitis and gangrene are also uncommon complications. We propose that the involvement of blood vessels in leptospirosis must be understood as a sepsis-like, diffuse process of endothelial activation/damage rather than a classical systemic involvement.

There has recently been evidence against the role of autoimmunity.<sup>8</sup>

Serological tests are used most frequently for diagnosis of leptospirosis. MAT is still the golden standard in the diagnosis of leptospirosis. In our case, diagnosis of leptospirosis was established with positive MAT. Our patient was treated with intravenous ampicillin and oral tetracycline. Methylprednisolone 60 mg per day was given for skin vasculitis. Vasculitis secondary to presumptive leptospirosis was treated with long-term corticosteroids. Because the clinical features and diagnostic findings of leptospirosis are not specific, a high index of suspicion must be maintained for the diagnosis. Early clinical suspicion and laboratory confirmation of leptospirosis are essential since delayed diagnosis may increase mortality.

In conclusion, leptospirosis should be considered as a preliminary diagnosis and we recommend to start empiric treatment before confirmation of laboratory tests in patients with intra-hepatic cholestasis associated acute kidney injury with negative vasculitis panel. We documented findings of combined lesions of acute tubulointerstitial nephritis and acute tubular nephropathy and vasculitis with symmetrical peripheral gangrene of the lower extremities; an uncommon manifestation of leptospirosis, which resolved with steroid treatment.

#### **Declaration of conflicting interests**

The authors declared no conflicts of interest with respect to the authorship and/or publication of this article.

#### **Funding**

The authors received no financial support for the research and/or authorship of this article.

## **REFERENCES**

1. von Ranke FM, Zanetti G, Hochegger B, Marchiori E. Infectious diseases causing diffuse alveolar hemorrhage in immunocompetent patients: a state-of-the-art review. *Lung* 2013;191:9-18.
2. Cetin BD, Harmankaya O, Hasman H, Gunduz A, Oktar M, Seber E. Acute renal failure: a common manifestation of leptospirosis. *Ren Fail* 2004;26:655-61.
3. Ranawaka N, Jeevagan V, Karunanayake P, Jayasinghe S. Pancreatitis and myocarditis followed by pulmonary hemorrhage, a rare presentation of leptospirosis- a case report and literature survey. *BMC Infect Dis* 2013;13:38.
4. Bishara J, Amitay E, Barnea A, Yitzhaki S, Pitlik S. Epidemiological and clinical features of leptospirosis in Israel. *Eur J Clin Microbiol Infect Dis* 2002;21:50-2.
5. Yuzniahyati Y, Kenneth FR, Daisy Vanitha J. Leptospirosis: recent incidents and available diagnostics - a review. *Med J Malaysia* 2015;70:351-5.
6. Chakrabarti A, Nandy M, Pal D, Mallik S. A rare case of Weil's disease with alveolar haemorrhage. *Asian Pac J Trop Biomed* 2014;4:66-9.
7. Panagopoulos P, Terzi I, Karanikas M, Galanopoulos N, Maltezos E. Myocarditis, pancreatitis, polyarthritits, mononeuritis multiplex and vasculitis with symmetrical peripheral gangrene of the lower extremities as a rare presentation of leptospirosis: a case report and review of the literature. *J Med Case Rep* 2014;8:150.
8. Medeiros Fda R, Spichler A, Athanazio DA. Leptospirosis-associated disturbances of blood vessels, lungs and hemostasis. *Acta Trop* 2010;115:155-62.