

## Unusual Gouty Tophi Simulating Malignancy

Nurten TURHAN HAKTANIR,<sup>1</sup> Ayşe Tuba KURT,<sup>2</sup> Ahmet KARATAŞ,<sup>3</sup> Güray YILMAZ,<sup>4</sup> Yasemin KAYA<sup>3</sup>

<sup>1</sup>Department of Plastic Reconstructive and Aesthetic Surgery, Medical Faculty of Ordu University, Ordu, Turkey

<sup>2</sup>Department of Physical Medicine and Rehabilitation, Medical Faculty of Ordu University, Ordu, Turkey

<sup>3</sup>Department of Internal Medicine, Medical Faculty of Ordu University, Ordu, Turkey

<sup>4</sup>Department of Plastic Reconstructive and Aesthetic Surgery, Ünye State Hospital, Ordu, Turkey

Gout is a disorder of uric acid metabolism, characterized by deposition of monosodium urate crystals in joints and periarticular soft tissues as well as renal calculi and chronic nephropathy. The accumulation of crystals in the joints and periarticular soft tissues may cause recurrent episodes of inflammatory arthritis. Over the years, chronic form may occur with the presence of tophi and chronic arthropathy frequently in peripheral and rarely in axial joints. Surgical intervention is usually reserved for cases of recurrent attacks with deformities, severe pain and joint destruction.<sup>1</sup> In this article, we present a case of tophaceous gout with destructive bony changes simulating malignancy in X-ray which, to the best of our knowledge, has not been reported previously. In addition, we emphasize the importance of early debridement of tophi to avoid amputation.

### CASE REPORT

A 58-year-old male patient with 20-year history of gout presented with large, painful, ulcerated tophus with necrosis of the overlying skin on the first interphalangeal joint (IPJ) of right foot. He had used oral doses of colchicine (3x0.5 mg), amlodipin (10 mg), acarbose, and allopurinol (1x0.5 mg) for the treatment of gout, type 2 diabetes, and hypertension. Physical examination revealed an irregular lump on the right toe

including 1/2 distal of the metatarsal bone. There was an open wound with skin necrosis with a greyish, large and ulcerated nodule containing chalky material. Besides, widespread tophi on extremities and soft tissues were noticed (Figure 1). Many joints including the nonfunctional first IPJ of right toe were deformed.

Radiography showed destruction on the IPJ and adjoining metatarsal simulating a malignancy on the first finger of right foot. A similar lesion was noticed on the proximal IPJ of the third finger of the left hand (Figure 2). Besides, soft tissue swellings, periarticular erosions, and osteophytes were seen. On sonography, a few echogenic foci compatible with nephrolithiasis were detected in the right kidney.

Laboratory work up revealed elevated C-reactive protein (5.29 mg/L), erythrocyte sedimentation rate (99 mm/hour), blood urea nitrogen (26 mg/dL), creatinine (1.95 mg/dL), potassium (5.5 mmol/L), and hemoglobin A1c (6.8%) levels.

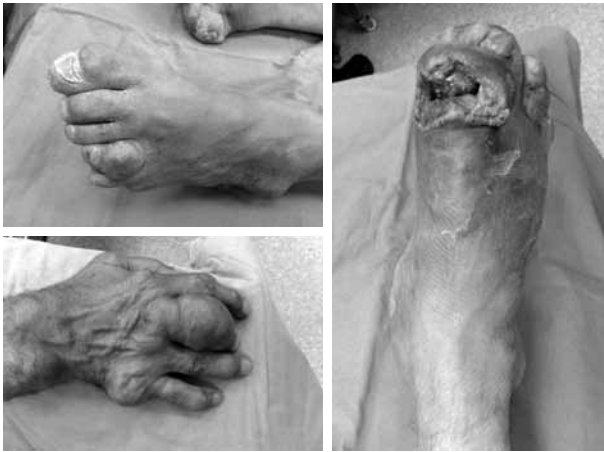Surgical debridement was carried out for necrosis and tophi, as well as the other minor ulcers (Figure 3). After the debridement, deformed right thumb was amputated including distal metatarsal owing to the remarkable dimensions of the ulcer and the complete destruction of the underlying joint. Cultures were found negative. Histopathologic examination revealed chronic

**Received:** September 14, 2015 **Accepted:** November 05, 2015 **Published online:** December 12, 2015

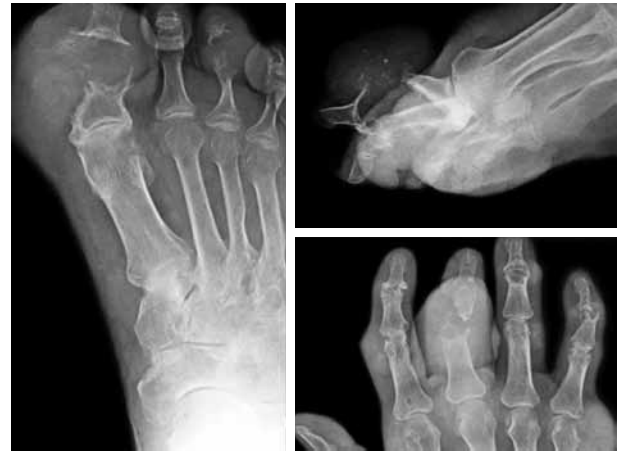**Correspondence:** Nurten Turhan Haktanir, MD. Ordu Üniversitesi Tıp Fakültesi Plastik Rekonstrüktif ve Estetik Cerrahi Anabilim Dalı, 52200 Ordu, Turkey.

Tel: +90 452 - 226 52 14 e-mail: nurth70@yahoo.com

©2016 Turkish League Against Rheumatism. All rights reserved.



**Figure 1.** Open wound with skin necrosis and a greyish, large and ulcerated nodule containing chalky material is seen on right toe including 1/2 distal of metatarsal bone (right), tophi on hands, feet, wrists, and ankles (right and left).



**Figure 2.** Radiographs of patient. Destructive changes on interphalangeal joint and adjoining metatarsal simulating a malignant tumor on first finger of right foot (left and upper right), a similar lesion is seen on proximal interphalangeal joint of third finger of left hand (lower left).

inflammatory process with foreign body giant cells which is compatible with gouty arthropathy. Ampicillin sulbactam (2 gr/day) and intravenous administration of paracetamol (4 gr/day) were initiated. Non-steroid anti-inflammatory agents could not be used because of the impaired renal function. A low protein diabetic diet with 2000 calories daily was ordered. The patient improved clinically and was discharged.


## DISCUSSION

By presenting this case, we would like to stress the critical importance of early surgical debridement of tophi on feet and hands to refrain from amputation. Our patient had an ulcerated tophus with skin necrosis on the first IPJ of right foot. Because of the chronicity and other morbid associations in elderly, such changes may be overlooked. Hereby, delayed surgical interventions may comprise amputation of the digits which is a more radical approach lowering the quality of life.

Surgical intervention is rarely necessary for gout and is usually limited to following indications: (i) functional, (ii) symptomatic, to control drainage and infection, reduction of pain, and decompression of nerves; (iii) cosmetic restoration; and (iv) metabolic, to lessen body total urates.<sup>2,3</sup> Removal of deposits from the feet can be achieved through curettage and debulking.

Also, some other minimal invasive techniques were reported previously.<sup>4-6</sup>

With the advent of the disease, a tophus may cause persistent pain that impairs foot function, superimposed infection and uncontrolled drainage, or enlargement of a digit. Thereby, amputation may become the last and undesired option.<sup>7</sup> However, limb-salvage is the main objective in the surgical treatment of tophi and other articular/periarticular masses. Our patient had type 2 diabetes which is a frequent and significant comorbidity of gout. Because the individuals with type 2 diabetes has an increased risk of gout, any tophus infection in foot may easily be overlooked in a patient with neuropathy.<sup>8</sup> Careful periodic examinations of the tophi may lower the undesired infectious complications that may lead to amputation surgery.



**Figure 3.** Enucleated tophi from right toe.

There is limited number of papers reporting gouty tophi that mimics malignancy radiologically.<sup>9-13</sup> The hand and foot lesions in our case had atypical radiographic findings with destructive bone and joint changes simulating a malignancy. Roentgenographic changes in gouty arthropathy are not sufficiently sensitive and specific for the diagnosis. Usually, acute gout does not show any abnormality in plain radiographs. Soft tissue prominence and discrete osteoporosis may rarely be present, particularly in the subchondral region.<sup>14</sup> Typical well-defined, “punched out,” periarticular erosions with overhanging edges are not seen until six to 12 years after the initial acute attack. Other radiographic characteristics are normal mineralization, joint space preservation, and asymmetric polyarticular distribution.<sup>15</sup> To the best of our knowledge, extensive bone destruction mimicking lytic bone metastasis and pathologic fracture has not been reported previously in the literature. There is only one paper reporting a single intraosseous gouty tophus in the second metacarpal causing a pathologic fracture and simulating a malignancy.<sup>9</sup> That case had an ill-marginated lytic and sclerotic lesion with a pathologic fracture and periosteal reaction. However, in our patient, there were destructive changes similar to a primary or metastatic malignant tumor both in right foot and left hand. Pathologic examination of the operated lesion showed a gouty tophus and did not reveal a malignancy.

In conclusion; (i) although rare, radiographic findings of destructive bone and joint changes simulating cancer (primary or metastasis) may be seen in tophaceous gout that may require histopathologic examination for the correct diagnosis; (ii) delayed surgical treatment may result in amputation of the digits. Thus, any tophus, especially in patients with diabetes should be meticulously monitored and treated without delay.

#### **Declaration of conflicting interests**

The authors declared no conflicts of interest with respect to the authorship and/or publication of this article.

#### **Funding**

The authors received no financial support for the research and/or authorship of this article.

## **REFERENCES**

1. Lee SS, Sun IF, Lu YM, Chang KP, Lai CS, Lin SD. Surgical treatment of the chronic tophaceous deformity in upper extremities - the shaving technique. *J Plast Reconstr Aesthet Surg* 2009;62:669-74.
2. Yetkin H, Takka S, Kanatli U. Surgical treatment of chronic tophaceous gout arthritis in the feet: a case report. *Foot Ankle Surg* 1999;5:155-7.
3. Kumar S, Gow P. A survey of indications, results and complications of surgery for tophaceous gout. *N Z Med J* 2002;115:109.
4. Lee SS, Lin SD, Lai CS, Lin TM, Chang KP, Yang YL. The soft-tissue shaving procedure for deformity management of chronic tophaceous gout. *Ann Plast Surg* 2003;51:372-5.
5. Lee JH, Park JY, Seo JW, Oh DY, Ahn ST, Rhie JW. Surgical treatment of subcutaneous tophaceous gout. *J Plast Reconstr Aesthet Surg* 2010;63:1933-5.
6. Khandpur S, Minz AK, Sharma VK. Chronic tophaceous gout with severe deforming arthritis. *Indian J Dermatol Venereol Leprol* 2010;76:69-71.
7. Ertuğrul Sener E, Güzel VB, Takka S. Surgical management of tophaceous gout in the hand. *Arch Orthop Trauma Surg* 2000;120:482-3.
8. Wijnands JM, van Durme CM, Driessen JH, Boonen A, Klop C, Leufkens B, et al. Individuals With Type 2 Diabetes Mellitus Are at an Increased Risk of Gout But This Is Not Due to Diabetes: A Population-Based Cohort Study. *Medicine (Baltimore)* 2015;94:1358.
9. Yaegashi Y, Nishida J, Oyama K. Gouty tophus of the second metacarpal simulating a malignancy with pathologic fracture. *J Hand Surg Am* 2013;38:208-9.
10. Amber H, Singh VA, Azura M. Gouty tophi mimicking synovial sarcoma of the knee joint. *Arch Rheumatol* 2012;27:208-11.
11. Chaoui A, Garcia J, Kurt AM. Gouty tophus simulating soft tissue tumor in a heart transplant recipient. *Skeletal Radiol* 1997;26:626-8.
12. Watura C, Saifuddin A. Tophaceous calcium pyrophosphate dihydrate deposition disease of the knee mimicking an aggressive soft tissue tumour. *BMJ Case Rep* 2014;2014.
13. Ryckaert T, Crevits I, Brijs S, Debakker G, Rosseel F, Tieleman A, et al. Pseudotumoral tophaceous involvement of the achilles paratenon. *JBR-BTR* 2015;98:34-6.
14. Kang M, Prakesh M. Crystal Deposition arthropathy (Gout). In: Chowdhury V, Kumar Gupta A, Khandelwal N, editors. *Diagnostic Radiology: Musculoskeletal and Breast Imaging*. 3rd ed. New Delhi: JP Medical Ltd 2012. p. 129-30.
15. Schlesinger N. Diagnosis of gout: clinical, laboratory, and radiologic findings. *Am J Manag Care* 2005;11:443-50.